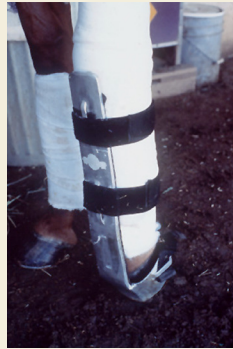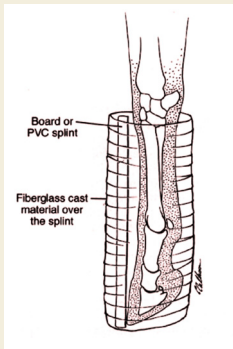
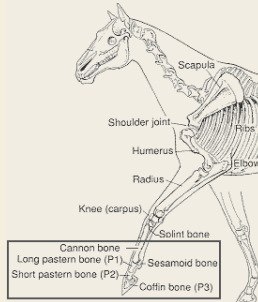


Emergency Splinting Techniques for Stabilizing Equine Fractures

DISTAL FORELIMB FRACTURES

Includes cannon bone, long and short pastern bones and sesamoid bone.

The goal of splinting is to align the bony column and protect the soft tissues in the fetlock and pastern from excessive compression. The splint should cover the entire foot and extend to the upper portion of the cannon bone. A commercially available splint that has been specifically designed for these injuries is the Kimsey Leg Saver. This splint is easy to apply and is very effective for stabilizing all of the above-listed injuries.



(Left) The dorsal board splint must incorporate the entire foot to be effective. (Right) The Kimsey Leg Saver is easy to apply and is very effective for stabilizing lower limb fractures and suspensory apparatus failures.

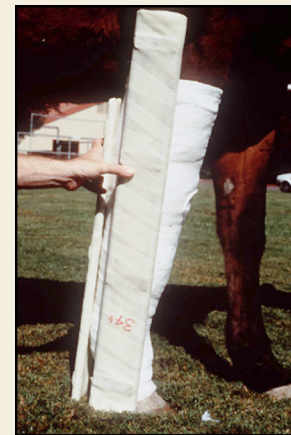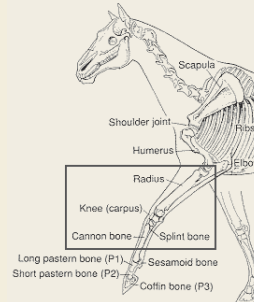
Splint Application

- Apply a bandage of medium thickness from the coronary band to the upper portion of the cannon bone.
- Place a board or other rigid material against the front lower portion of the limb and secure it with nonelastic tape or casting material. It is important to include the entire foot within the splint to avoid causing more trauma at the fracture site.
- A Kimsey Leg Saver can be applied in place of the dorsal splint.

MID-FORELIMB FRACTURES

Includes cannon bone, knee and forearm.

The goal of splinting is to realign the bony column and prevent the lower limb from moving in four directions. This is best accomplished by applying two splints placed at right angles: a caudal (on the back of the leg) splint placed from the ground to the top of the olecranon (point of elbow), and a lateral (on the side of the leg) splint placed from the ground to the elbow.



Two splints are placed at right angles to align the bony column and prevent movement.

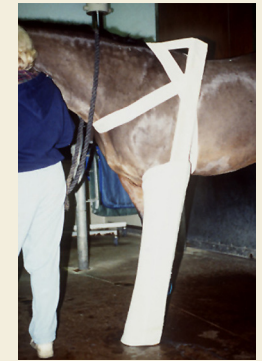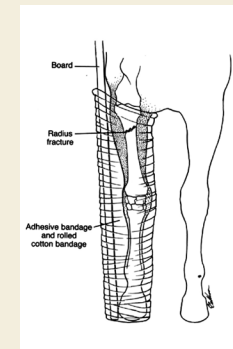
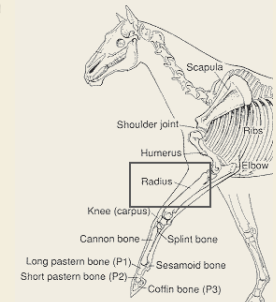
Splint Application

- Apply a bandage of moderate thickness from the coronary band to the highest point of the elbow. Typically, three levels of bandage are required to reach the elbow.
- Place a caudal splint extending from the ground to the point of elbow against the limb and secure it with nonelastic tape.
- Place a lateral splint extending from the ground to the elbow joint against the limb and secure it with nonelastic tape.
- The entire foot should be included in the splint to increase stability.

MID-FOREARM FRACTURES

Includes the forearm above the knee.

The goal of splinting is to realign the bony column, prevent movement of the bone in all directions, and protect the skin on the inside of the limb from being lacerated by the sharp bone ends. Two splints should be applied at right angles: a caudal (on the back of the leg) splint placed from the ground to the top of the olecranon (point of elbow), and a lateral (on the side of the leg) splint placed from the ground to above the shoulder to prevent lateral movement of the limb.



(Left) With the lateral splint placed above the scapulohumeral joint, the lower portion of the limb cannot deviate laterally. (Right) As shown, the splint is placed to the level of the withers to ensure that it crosses the shoulder joint.

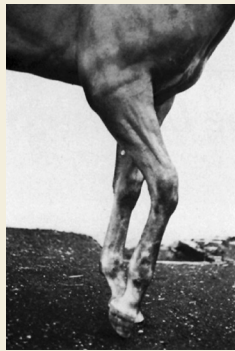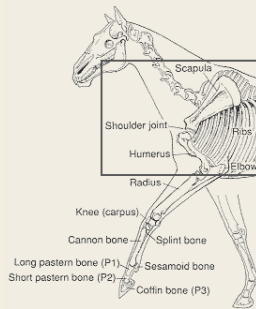
Splint Application

- Apply a bandage of moderate thickness from the coronary band to the highest point of the elbow. Typically, it will require three levels to stack the bandage to the elbow.
- Place the caudal splint from the ground to the highest point of the elbow and secure it with nonelastic tape.
- Place the lateral splint from the ground to above the shoulder joint and secure it with nonelastic tape.
- Secure the highest portion of the splint to the trunk, as shown, by wrapping elastic bandage material around the neck and chest, through the forelimbs, over the withers, and under the girth in a figure-eight pattern.

PROXIMAL FORELIMB FRACTURES

Includes the elbow, shoulder above elbow, and shoulder blade.

The goal of splinting is to fix (lock) the knee (carpus). By doing so, horses that have lost triceps function will immediately become more comfortable. Fixing the knee and aligning the bony column is best achieved by applying one splint that extends from the ground to the elbow on the caudal (back of the limb) aspect of the limb.



(Left) Horses that have lost triceps function cannot fix the knee and cannot bear weight on the limb. (Right) A single splint is applied on the upper-back aspect of the limb to fix the knee and realign the bony column.

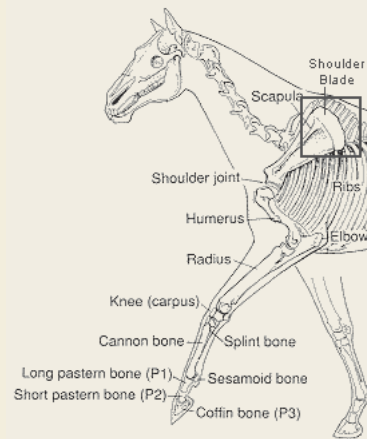
Splint Application

- Place a bandage of medium thickness from the coronary band to the highest point of the elbow. Typically it will require three levels to stack the bandage to the elbow.
- A caudal splint extending from the ground to the elbow point is taped to the limb with nonelastic tape.

PROXIMAL LIMB FRACTURES

Includes shoulder blade.

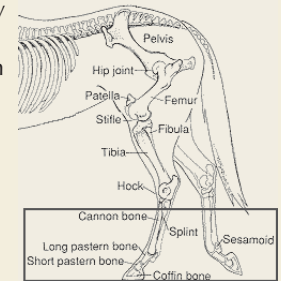
Splinting is contraindicated, either above or below the fracture, and could increase trauma directly at the fracture site.



DISTAL HINDLIMB FRACTURES

Includes lower cannon bone, sesamoid bone, and long and short pastern bones.

The goal of splinting, as with the forelimb, is to align the bony column and protect the soft tissues in the fetlock and pastern from excessive compression. This can best be accomplished by applying a board or other rigid material to the lower-back aspect of the limb. It is very important to incorporate the entire foot in the flexed position to avoid causing more trauma at the fracture site. A Kimsey Leg Saver splint is as effective as a plantar splint.



(Left) A plantar splint (on the back of the leg), incorporating the entire foot, is placed to realign the bony column and protect the plantar soft tissues. (Right) A Kimsey splint is easy to apply and is very effective for stabilizing these fractures.

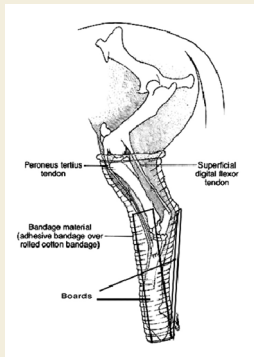
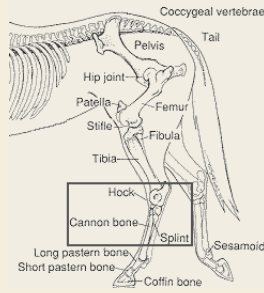
Splint Application

- Apply a bandage of medium thickness from the coronary band to the top of the cannon bone.
- Place a board or other rigid material to the lower-back aspect of the limb and secure it with nonelastic tape. It is very important to incorporate the entire foot within the splint to have it be effective. If the entire foot is not incorporated, it will cause more trauma at the fracture site.
- A Kimsey Leg Saver is as effective as a plantar splint.

MID-HINDLIMB FRACTURES

Includes cannon bone and hock.

The goal of splinting is to realign the bony column and prevent movement in any of the four directions (back, front and sides). This is best accomplished by applying two splints placed at right angles: a caudal (on the back of the leg) splint placed from the ground to the highest point of the hock, and a lateral (on the side of the leg) splint placed from the ground to the hock. For fractures involving the tarsal bones, the lateral splint should be bent in the shape of the hindlimb to extend the splinting device higher up.



(Left) A lateral and caudal splint, placed to the highest point of the hock, can stabilize these fractures. (Right) A lateral splint, bent in the shape of the limb, should be used for tarsal bone fractures and dislocations or simply for greater stability.

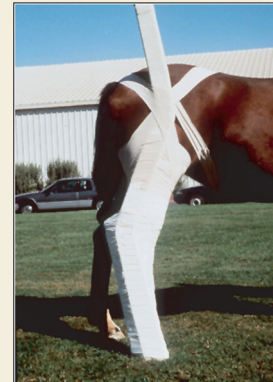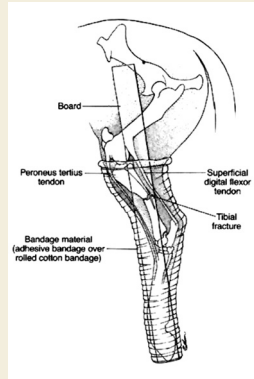
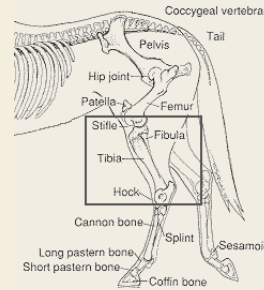
Splint Application

- Apply a bandage of moderate thickness from the coronary band to the stifle (see skeleton). Typically, three levels of bandage are required to reach the appropriate level.
- Place a caudal splint extending from the ground to the highest point of the hock against the limb and secure it with nonelastic tape.
- Place a lateral splint extending from the ground to the highest point of the hock, or to the stifle (as in photograph), against the limb and secure it with nonelastic tape.
- The entire foot should be included in the splint.

MID-PROXIMAL HINDLIMB FRACTURES

Includes hock, tibia, fibula and stifle (gaskin area).

Sharp bone ends from these fractures can traumatize skin, muscle and surrounding neurovascular structures every time the limb is flexed or extended. The goal of splinting is to realign the bony column and prevent fracture collapse as well as movement of the limb. This is best accomplished by applying one lateral splint (on the side of the leg) extending from the ground to the hip. A caudal splint (on the back of the leg) is contraindicated.



(Left) A lateral splint placed from the ground to the hip will effectively stabilize complete tibial fractures. (Right) The upper portion of the lateral splint is secured with elastic tape placed over the hip in a figure-eight pattern.

Splint Application

- Apply a bandage of moderate thickness from the coronary band to the stifle. Typically, three levels of bandage are required to reach the appropriate level.
- Place a lateral splint extending from the ground to the hip against the limb and secure it with nonelastic tape.
- Secure the upper portion of the splint with elastic tape placed over the hip, through the legs, under the flank, and over the lumbar spine in a figure-eight pattern.
- It is important to incorporate the entire foot in the splint.

MID-PROXIMAL HINDLIMB FRACTURES

Includes the femur between the stifle and the hip joint and the pelvis.

Splinting for fractures located above the stifle is contraindicated and could increase trauma directly at the fracture site.

