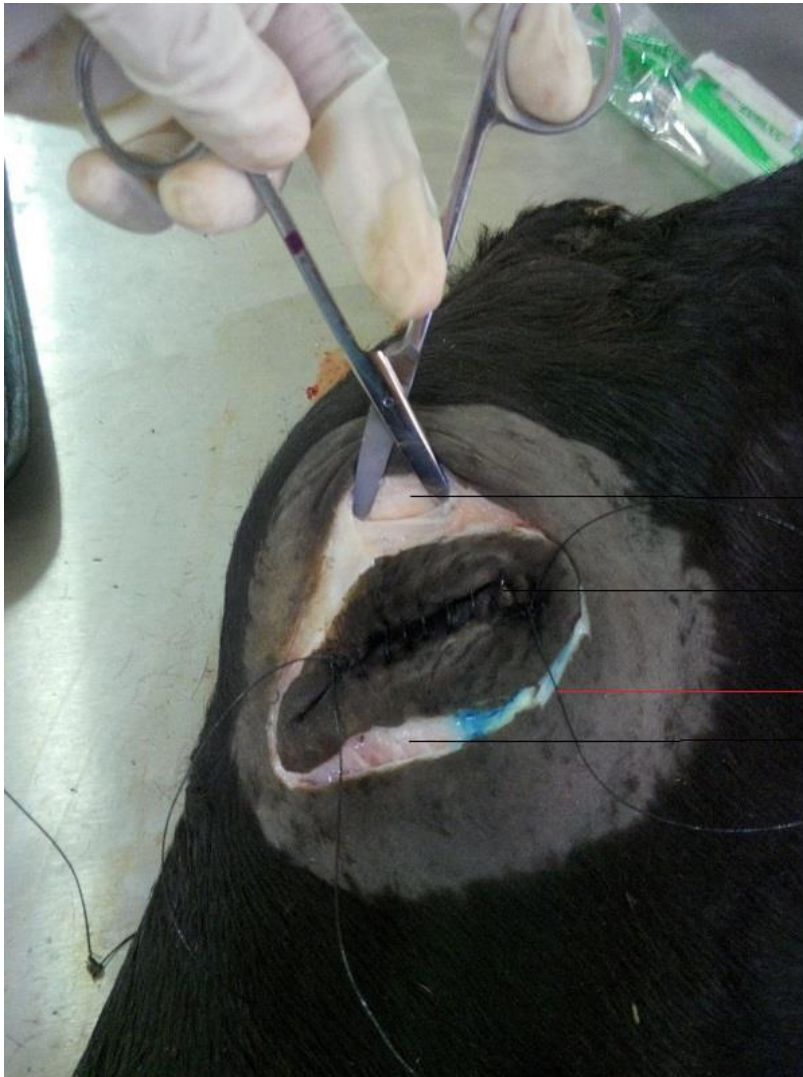


Bovine Eye Removal Surgery

Surgical Technique

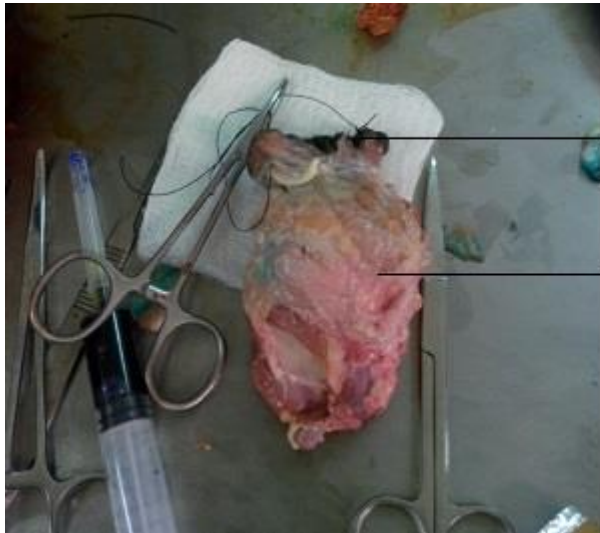

Small slit made using a curved scissors to begin blunt dissection

Eyelid closed using a simple continuous suture pattern

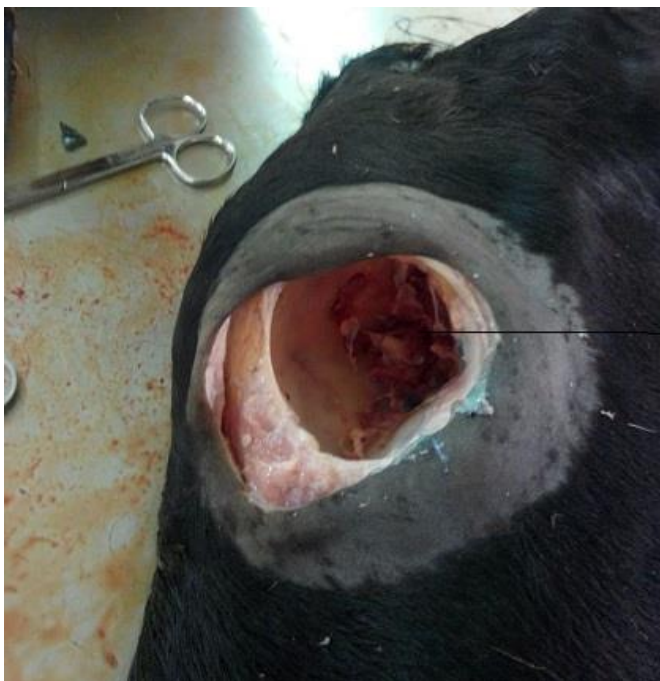Note the suture ends left long to act as traction to pull globe

Transpalpebral incision made into skin and subcutaneous tissue

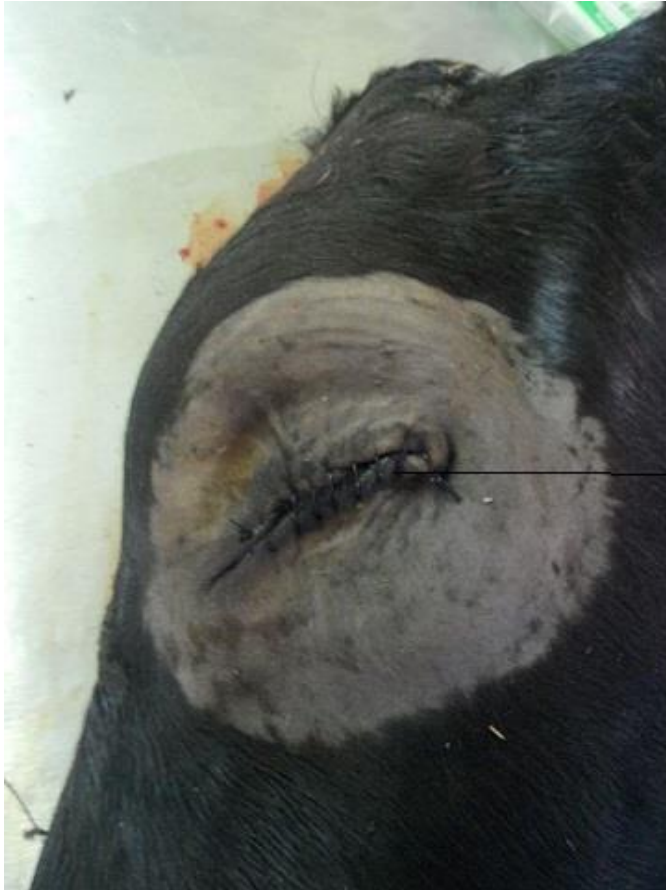

— Eyelid

— Globe and associated muscles and adipose tissue after exenteration



— Orbit after exenteration



Skin around the orbit sutured shut using a simple continuous suture pattern.

Note: Can also use simple interrupted or horizontal mattress suture patterns