

Trimming Hooves

Condition of the feet and legs on dairy cattle shouldn't be taken lightly. A cow with sore feet may realize losses in milk production, diminished breeding efficiency and decreased salvage value in the case of severe lameness. As the number of cows in confinement increases, the need for periodic hoof trimming is necessary for cows to reach their full genetic potential.

Hoof trimming is very labor intensive, which is why many times it is neglected. Before you can begin hoof trimming, you must understand what the correct hoof shape is. *Figure 1* shows a diagram of a correctly shaped hoof. Notice the 45° angle of the hoof to give the greatest amount of shock absorption through the pastern yet provide plenty of heel depth. Another way to get an idea of a correctly shaped heel is to look at a young calf's hoof (1-2 months old). Toes on each hoof should be about equal length, with all four feet approximately the same shape. The hind feet are likely to get longer on the toes than the front feet, and may need trimming more often.

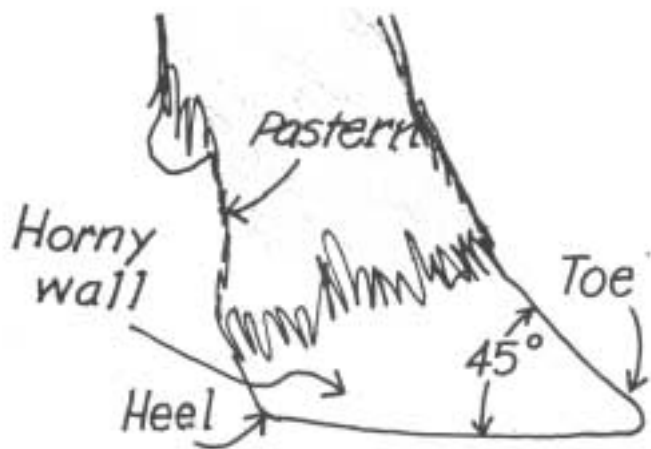


Figure 1

Trim the feet of cows that show excessive hoof growth or signs of lameness. It is best to trim hooves when cows are in the latter part of lactation so you don't disturb milk production. One of the more popular methods of restraining a cow is to use a tilt table (*Figure 2*). This allows for total restraint of the cow, but does have the disadvantage of making it more difficult to check for the correct foot angles.

Assemble the proper equipment, shown in *Figure 3*. Use a couple of hoof knives (search knives), a rasp (some prefer



Figure 2



Figure 3

an electric sander), hoof nippers and gloves to protect your hands. Be sure the hoof knives are sharp. This reduces the force required to use them, making them much safer.

Hoof trimming should be supervised or taught by a veterinarian or professional hoof trimmer until you become accomplished at the skill. When the cow is restrained properly, begin with the hoof knife. *Figure 4* shows removal of old hard sole towards the toes. You should remove very little tissue from the heels, but take more off as you pull towards the toes. The goal is to get the length in proper proportion to the foot shape desired.

Avoid cutting too deep. Generally, it is better to under trim than over trim. If you see any pink tissue, stop before you draw blood. There are exceptions to this, in the case of abscesses or other foot problems.

After the sole is sufficiently pared down and no problem area is spotted, use the nippers to shorten the toe and shape the hoof (*Figure 5*). Cut from the underside of the hoof.

Foot Care



Figure 4

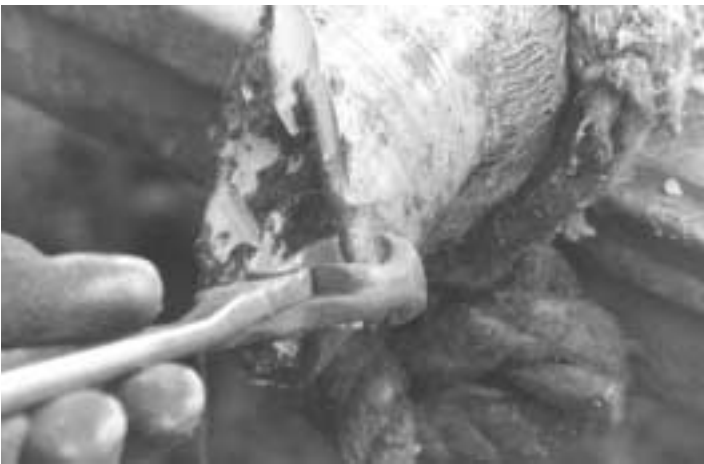

Figure 5

Again, take small bites at a time so you don't injure the foot. The finished hoof should be slightly concave so most of the weight is supported by the outer horny wall. The hoof should set flat when placed on the ground. This can be checked while the cow is still on the table by placing a small board on the bottom of the hoof. A common mistake is to trim too much from the toe, leaving a rounded bottom to the hoof.

Finish the hoof by rasping or sanding the rough areas so you don't leave an area for bacterial growth. Be careful so you don't get the foot hot if you use a disk sander. The excess heat can cause internal damage and abnormal hoof growth. Some trimmers coat the hooves with iodine when they're finished, to help dry the hoof and act as a bactericide.

Several other practices to compliment your hoof trimming are:

1. Keep cattle areas dry. Wet floors tend to keep the soles soft, so they are subject to more mechanical injuries and foot rot.
2. Use a copper sulfate foot bath to help control foot rot.
3. Allow the cows plenty of room to exercise so they wear feet down.
4. Don't turn freshly trimmed cows out on rough, frozen ground.
5. Use a well-balanced ration with an adequate amount of fiber.
6. Seek out professional help if needed.

Hopefully, a few of these ideas may improve hoof care in your herd.

Treating Sole Abscesses

Lameness caused by a sole abscess can occur in any herd. Sole abscesses generally occur in the hind feet and most often during the first half of lactation. More foot problems are seen in the winter months because wet floors soften the soles of feet, making them more susceptible to abscesses and other injuries.

Sole abscesses are usually a result of a puncture wound from a nail or sharp object. They are also caused by cows walking on overgrown hooves. This causes bruising and results in an abscess.

A sole abscess needs to be treated promptly to prevent the spread of infection into the toe joint, causing permanent injury. A novice should always seek the help of a professional hoof trimmer or veterinarian.

Lift the infected foot and wash it with a sanitizing solution (*Figure 1*). This allows for better observation of the foot. Usually a sole abscess won't cause the foot to swell, but if you tap on the bottom of the hoof with the handle of the hoof knife, the cow exhibits pain.



Figure 1

The next step is to remove excessive tissue from the bottom of the sole as you would for regular hoof trimming. Remember to remove more from the toe than the heel. Once the sole is pared down, try to find a spot where a black mark or line shows through the cleaned off sole. This black mark is usually from dirt that got into the puncture wound, or where some puss was released, leaving an opening that was contaminated by dirt and manure. Dig out the sole of the foot, following the black line to the abscess. Pus usually

s spurts out of the abscess, leaving a hole in the foot. To provide adequate drainage, pare-out the wound area and dead tissue, as shown in the heel abscess in *Figure 2* and the toe abscess in *Figure 3*.

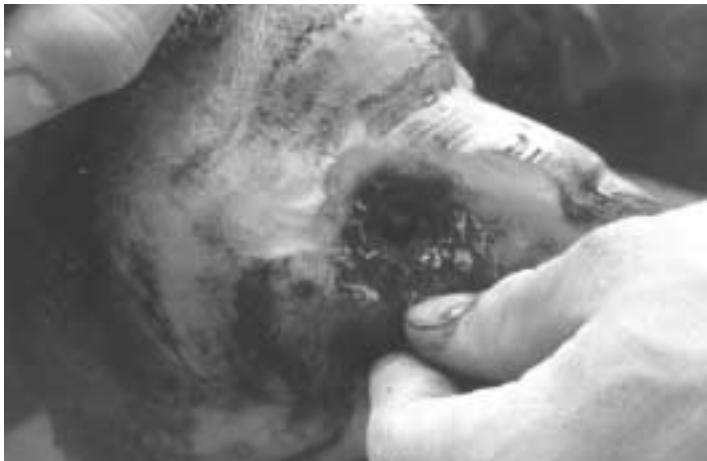

Figure 2

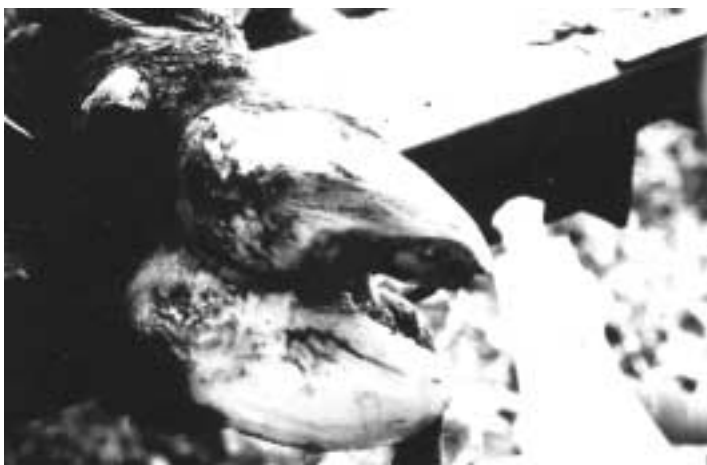

Figure 3

After you provide adequate drainage, it is important to use some type of topical antibiotic or sulfa drug to help promote healing. *Figure 4* shows the use of a mastitis infusion tube to apply antibiotic directly into the wound to prevent infection. Be sure to consult your veterinarian on milk withholding when using antibiotics. Follow labels properly. Once the antibiotic is applied, copper sulfate may also be used as a wound dressing. It can prevent the open wound from becoming a foot rot problem.

After applying the wound dressing, pack the affected claw with cotton and wrap it to help protect the wound (*Figure 5*). Reusable urethane boots are also available for this purpose. The wrapping will wear off in a couple of weeks on its own.

Foot Care

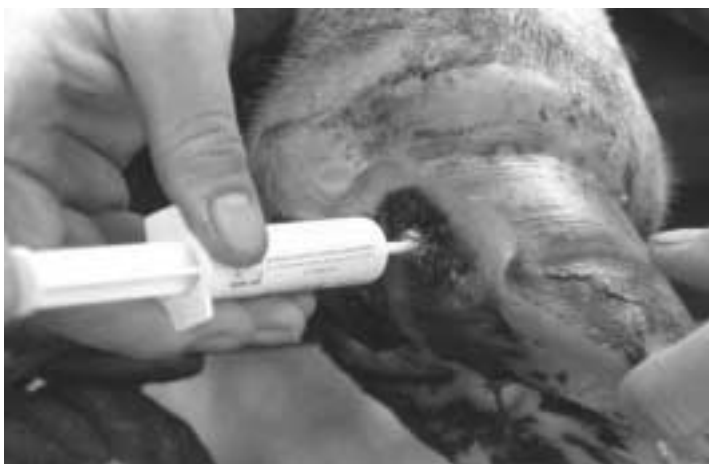

Figure 4

If the claw has had an extreme amount of tissue removed, it may be advisable to glue a wooden block to the bottom of the unaffected hoof. This will keep weight off the injured claw and prevent further mechanical injury.

An important role of the dairy herdsman is to decrease the incidence of sole abscesses through good management. Develop a regular hoof trimming program. It's best to trim cows' feet toward the end of lactation or as they are being dried off. Keep cows on well balanced diets with adequate amounts of fiber. High concentrate diets tend to lead to more foot problems. Also select cows for better feet and legs. Prevention and early diagnosis are keys to eliminating sole abscess problems.



Figure 5

Using Footbaths

Foot rot and heel erosion are two common foot ailments of cattle leading to lameness and decreased production. Both are caused by a bacterial infection. Hairy heel warts are also a common cause of lameness. All three can be prevented or reduced with proper sanitation and judicious use of a footbath. They are often misdiagnosed. Foot rot is also referred to as foul-in-the-foot. Common names for heel erosion are stable rot or stall rot. Other names for hairy heel warts include interdigital dermatitis and strawberry heel.

Cows with foot rot suddenly become noticeably lame. Generally, only one foot is affected. It usually begins with a bacterial infection between the toes that, left untreated, can spread into the points of the foot and cause permanent damage. The foot swells most noticeably in the pastern area (*Figure 1*). If you stand behind the cow, you can see the swelling forcing the claws apart. The cow may run a temperature with a drop in milk production. There is a characteristic foul smell from between the toes. After foot rot is diagnosed, administer antibiotics or sulfonamides, following proper dosage and withdrawal times. Wash the area between the toes with a mild disinfectant, and remove any loose, decaying tissue. Trim diseased hoof tissue.

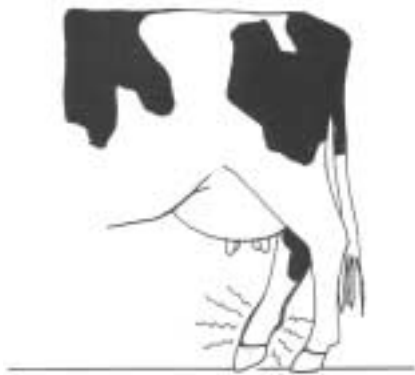

Figure 1

Heel erosion occurs in different stages with varying symptoms. Initial symptom is a wet, clear or gray-colored inflammation on the skin between the claws. The initial stages generally do not cause lameness, fever or noticeable production drop. Antibiotics generally have no effect. In the next stage of infection, the bacteria can infect the heel of the hoof, causing heel erosion (*Figure 2*). This can lead to degeneration of the hoof, abnormal hoof growth, sole abscesses and permanent hoof damage. Heel erosion is most prevalent in confinement.

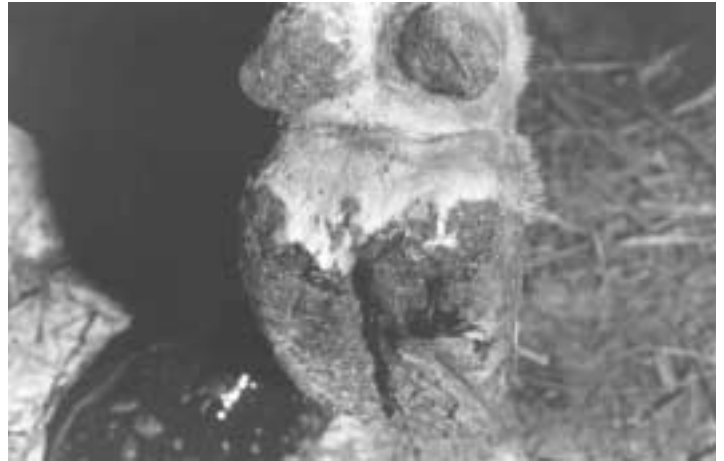

Figure 2

Typically, hairy heel warts are first seen on the heel bulbs of the hind feet. They occur less frequently on the front feet. They can also occur in the interdigital area toward the front of the foot. The warts may have projections resembling hairs. The lesions can become ulcerated, with erosion of the area between the skin and hoof.

Proper use of footbaths can greatly reduce infectious foot problems in cattle. Footbaths can be purchased commercially or constructed inexpensively with exterior plywood as the base and 2x6's for the sides. A bead of silicone caulk or sealant between the 2x6's and the plywood prior to assembly will help seal the joints. The footbath solution will act as a preservative for the wood.

The bath should be at least 8 ft. long and wide enough so cows can't walk around it. Generally, the footbath is placed in the exit lane of the milking parlor so cows walk through it twice a day (*Figure 3*). In stall barns, the bath may be located outside the exit door so cows walk through it as they exit and enter.

Copper sulfate and zinc sulfate are two compounds shown to be effective against foot problems when placed in a foot bath at 5%. To calculate the gallon capacity of the footbath, multiply length x width x depth x 7.46. There are 7.46 gallons in a cubic foot. One gallon weighs 8 lbs. For a 5% copper sulfate footbath, add 4 lb. copper sulfate per 10 gallons of water (*Figure 4*). Tetracycline and Oxytetracycline at .1% or Lincomycin at .01% have shown to be effective against hairy heel warts.

Once the problems have been reduced, cutting the concentration to 2½% should be sufficient. The footbath should be emptied and replenished if it becomes diluted with waste. This might be multiple times per day on large herds or weekly in small herds. One practice is to replenish the bath



Figure 3

and allow cows to walk through it for 4 days, then dump it and leave it empty for 3 days. On the eighth day, replenish and repeat the cycle. Another option might be to use copper sulfate for 5 days and Lincomycin for 2 days. You may have to experiment to find the program best for your situation.



Figure 4

Other considerations include:

- The footbath should be deep enough to submerge the foot past the hairline.
- If introducing a footbath to cows for the first time, just fill with clear water for a day until cows get used to stepping through it.
- To lessen contamination of the footbath, a clear water footbath can be placed prior to the chemical bath to cleanse the cow's hoofs. Suspect cow's feet can be sprayed off in the parlor so that they have better contact with the chemical in the footbath.
- Place footbaths in places where they are easy to clean and maintain.
- If multiple groups of animals work through a bath, replenish the footbath so that each group gets the fresh solution in rotation.
- Solutions that are mixed too strongly can harm the skin on a cow's foot or may splash up on a cow's teats. Do not use concentrations greater than 5%.
- If the skin on the cow's feet becomes irritated, discontinue the footbath for 2 weeks. If the condition persists, consult your veterinarian.
- Try to provide cows with a fairly clean, dry environment after they walk through the bath. A footbath will have little effect if the cows walk from it into 6 inches of muck.
- When a footbath is emptied, the solution should not cause contamination problems if it is added to the barn manure waste.
- Some dairy farms have found success preventing hairy heel warts with a copper sulfate and lime paste. It is recommended to mix 5 lbs. of copper sulfate in 25 gallons of water in the footbath. After it dissolves, mix 25 lbs. of hydrated lime in with a hoe to form a paste.

A footbath will not solve lameness problems if there are other weak points in management. The ration needs to be balanced, especially assuring adequate fiber level. Hooves need to be properly trimmed. Improper trimming can cause more harm than good by putting uneven stresses on the hoof. Cows' feet should be kept as dry as possible. Giving cows daily access to a drylot or pasture can alleviate foot problems.