

Summary of Otitis Interna

Causes:

- Bacterial infections
- Fungal or yeast infections

Clinical Signs

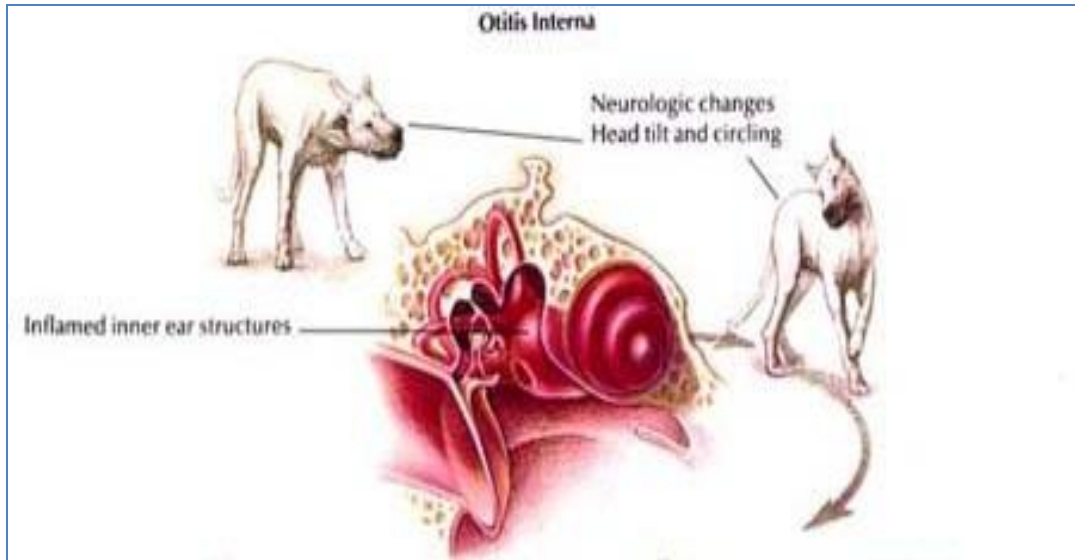
- Impaired function of vestibulocochlear nerve (CN VIII):
- Hearing loss
- Head tilt
- Circling
- Leaning or falling toward the affected side
- General incoordination
- Spontaneous horizontal nystagmus
- Extension of infection to brain:
- Meningitis
- Meningoencephalitis
- Abscesses
- Congenital predisposition: Doberman breed

Diagnosis

- Requires CT or MRI

Treatment

- Surgical exploration
- Ventral bulla osteotomy if indicated followed by 1 – 3 months of antibiotic therapy



REFERENCES:

http://www.merckmanuals.com/vet/eye_and_ear/otitis_media_and_interna/overview_of_otitis_media_and_interna.html

http://www.vetbook.org/wiki/dog/index.php/Otitis_interna

http://www.vetbook.org/wiki/dog/index.php/Otitis_media

http://www.merckmanuals.com/vet/eye_and_ear/otitis_externa/overview_of_otitis_externa.html