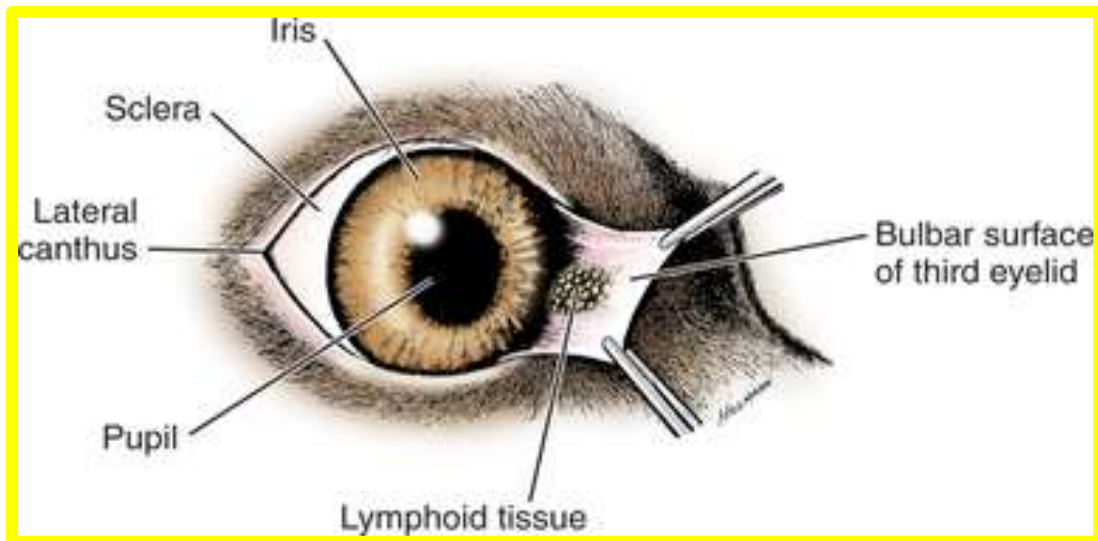


ANATOMY OF THE THIRD EYELID



The third eyelid of the ruminant is composed of a T-shaped cartilage covered with mucosa visible at the medial canthus of the eye. The third lid moves over the cornea dorsolaterally. It has glandular tissue that secretes material similar to the lacrimal glands.