

Eye Conditions in Cattle

Phil Scott DVM&S, DipECBHM, CertCHP, DSHP, FRCVS

Infectious Bovine Keratoconjunctivitis (IBK, "Pink eye", New Forest Disease").

IBK is a highly contagious disease caused by a bacterium *Moraxella bovis* that can spread rapidly during the summer months.

It is more commonly seen in young stock than adults. Head and nuisance flies can act as mechanical vectors for *M. bovis* and dust can be a risk factor. The pain associated with this condition is more intense in strong sunlight.

Most eye lesions are selected for treatment on the basis of obvious tear-staining of the face which becomes increasingly purulent matting the lashes and hair of the face. There is marked pain when the eye is exposed to direct sunlight. The ocular lesions are very painful and disrupt grazing patterns causing poor performance and even weight loss. Bilateral lesions cause temporary blindness and the affected animals tend to wander aimlessly about.

- tear-staining of the face
- pus matting the lashes and hair of the face
- conjunctivitis
- corneal ulceration
- pain when the eye is exposed to direct sunlight



Fig 1: IBK lesions are very painful and disrupt grazing patterns causing poor performance and even weight loss.



Fig 2: There is marked pain when the eye is exposed to direct sunlight. Note the obvious tear-staining of the face.

Spontaneous recovery may occur in mild cases three to five days after clinical signs are first observed, and is complete two weeks later. In severe cases, ulceration may progress to corneal perforation but this is uncommon.

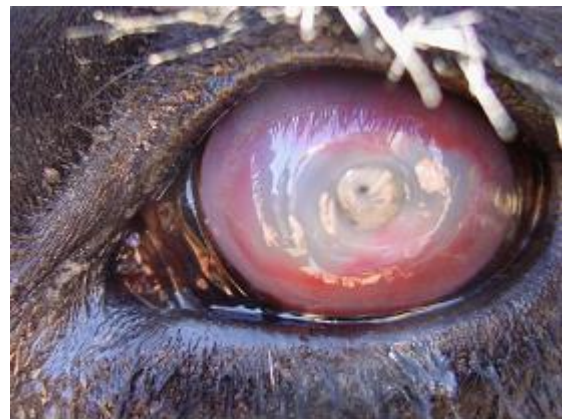

Fig 3: Advanced case of IBK showing deep corneal ulceration

The main differential diagnoses your veterinary practitioner will consider include

- foreign bodies (e.g. grass awns) within the conjunctival sac,
- bovine iritis
- infectious bovine rhinotracheitis (IBR).

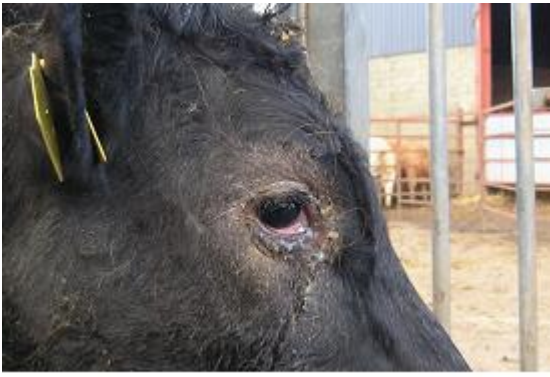

Fig 4: IBR is one of the main differential diagnoses your veterinary practitioner will consider.

Prompt treatment is essential. Topical ophthalmic antibiotic cream containing cloxacillin is commonly used. Antibiotic injection (penicillin, oxytetracycline or ceftiofur) into the dorsal bulbar conjunctiva is the best treatment but can be difficult to achieve in fractious cattle and requires good restraint. Injection into the upper palpebral conjunctiva is commonly used but it should be noted that this technique will not give residual antibiotic levels in the eye and relies on leakage onto the cornea from the injection site. This technique has no advantage over systemic injection except the much lower cost because of the smaller antibiotic dose.

When subconjunctival or topical treatment is not practical then single dose long acting oxytetracycline or florfenicol, have been reported to be effective but will prove more expensive.

In severe cases suturing the eyelids together using mattress sutures can be undertaken under local anaesthesia together with an auriculopalpebral block. The sutures must not contact the cornea and are removed after - two weeks. Temporary adhesive eye patches can also be used to provide protection from environmental conditions. Severely affected cattle should be housed with ready access to food and water.

Metaphylactic injection of all at-risk cattle with a single intramuscular injection of long-acting oxytetracycline could be considered in severe epidemics but there are no supporting field data.

Management/Prevention/Control measures

Outbreaks of IBK may occur after the introduction of purchased stock therefore, whenever possible, all new stock should be managed separately as one group away from the main herd. Fly control using ear tags and pour-on insecticides is never absolute

and repeated treatments prove costly. Development of immunity following infection is variable.

- All new stock should be managed separately
- Fly control using ear tags and pour-on insecticides

Bovine Iritis (Syn: "silage eye")

Bovine iritis, colloquially known as "silage eye" in the UK, is a common cause of uveitis in cattle of all ages fed winter rations of baled silage/haylage.

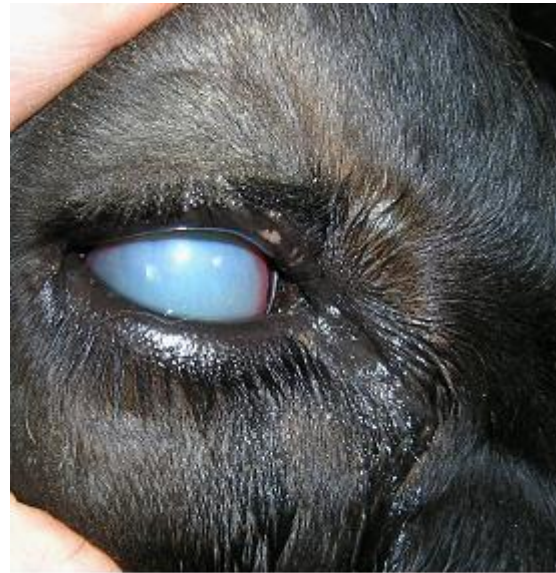

Fig 5: With silage eye there is a bluish-white opacity of the surface of the eye within two to three days.

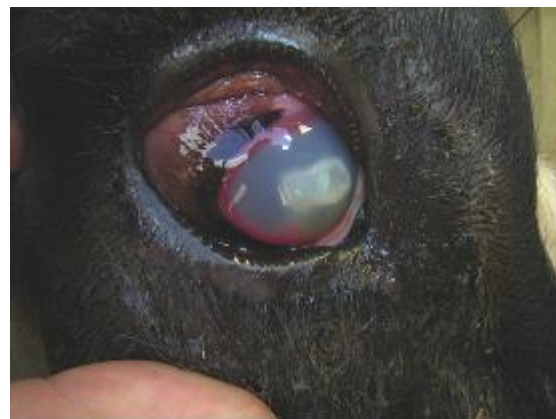

Fig 6: Bulges often appear in the iris with white discoloration

Clinical presentation

The initial presenting signs are excessive tear-staining, blinking and forced closure of the eyelids, and pain from direct sunlight. Within two to three days there is a bluish-white opacity of the surface of the eye (cornea). Regression of ocular lesions takes several weeks without treatment.

- excessive tear-staining, initially clear, becoming sticky and purulent
- blinking
- forced closure of the eyelids
- bluish-white opacity of the surface of the eye which can become yellow as pus develops
- Bulges in the iris, with white discolouration.
- Very painful particularly in direct sunlight

Treatment

There is a good response to combined subconjunctival injection of oxytetracycline and dexamethasone (2-3ml of 5 or 10% oxytetracycline mixed with 0.5-1ml soluble dexamethasone) in acute cases administered by the veterinary practitioner.

Management/Prevention/Control measures

Big-bale silage can be rolled out rather than placed in ring feeders to prevent cows burrowing their heads into the bale but this is impractical in most situations. Attention to detail when baling and wrapping silage and ensuring appropriate fermentation conditions should limit contamination with *L. monocytogenes* the cause of this problem. However, exposure to air for several days before the large bale is eventually eaten provides an ideal environment for *L. monocytogenes* multiplication.



Fig 7: Poor quality silage fed in ring feeders is the major risk factor for silage eye.



Fig 8: Perforations to the plastic wrap should be repaired immediately.

Ocular Squamous Cell Carcinoma (Syn: "Cancer eye")

Definition/Overview

Ocular squamous cell carcinomas are uncommon in northern Europe. They typically arise from the third eyelid or conjunctival membrane of the lower eyelid following exposure to prolonged ultraviolet radiation (sunlight).




Fig 9: Squamous cell carcinoma right eye

Clinical presentation

Initially there is closure of the eyelids and ocular discharge caused by mechanical irritation of the eye's surface.

Treatment

Early cases involving the third eyelid can be treated with surgical excision under local anaesthesia or with cryosurgery.

Enucleation, under standing xylazine sedation and retrobulbar block, may be required in advanced

cases involving the limb but may not be an option for commercial value cattle which must be culled for welfare reasons.

Management/Prevention/Control measures

Select cattle with pigmented skin surrounding the eyelids.

NADIS seeks to ensure that the information contained within this document is accurate at the time of printing. However, subject to the operation of law NADIS accepts no liability for loss, damage or injury howsoever caused or suffered directly or indirectly in relation to information and opinions contained in or omitted from this document.

To see the full range of NADIS livestock health bulletins please visit www.nadis.org.uk

“PREVENTION IS BETTER THAN CURE”

Plan for health with your vet - get a veterinary health plan

NADIS

Animal Health Skills