

How to Perform a Modified Standing Deep Digital Flexor Tenotomy at the Level of the Proximal Interphalangeal Joint

R. Wayne Waguespack, DVM, MS; and Fred Caldwell, DVM, MS

A modified standing deep digital flexor (DDF) tenotomy at the level of the proximal interphalangeal joint is an effective treatment option for horses with refractory acute or chronic laminitis. Performing the tenotomy at this level increases the release of the tendon compared with the effect of performing the procedure at a mid-metacarpal location. The modified procedure is technically easier to perform because of the size of the incision, the use of local anesthesia, and the ease of isolating the DDF tendon before transection. The modified technique also provides an alternative approach to repeating the transection in the mid-metacarpal region should surgery fail to produce satisfactory results. Authors' address: J. T. Vaughan Large Animal Teaching Hospital, College of Veterinary Medicine, Auburn University, Auburn, Alabama 36849; e-mail: rww001@auburn.edu. © 2009 AAEP.

1. Introduction

Horses with refractory acute and chronic laminitis can be difficult to treat. Veterinarians trying to manage these cases have three common objectives: (1) alleviate the pain associated with laminitis, (2) establish a more normal relationship between the distal phalanx and the hoof capsule, and (3) support the distal phalanx to prevent further alterations in its orientation within the hoof capsule (i.e., rotation or distal displacement). Medical and surgical therapies, including non-steroidal anti-inflammatory agents, peripheral vasodilators, hemorheologic agents, icing the feet, corrective shoeing, and deep digital flexor (DDF) tenotomy, are used extensively to treat horses with refractory laminitis.¹⁻⁵ Despite these treatment options, successful treatment of difficult laminitic cases is not always feasible.

Tenotomy of the DDF may be performed either in the mid-metacarpus or at the level of the proximal

interphalangeal (PIP) joint.^{1,3} Regardless of the site, the purpose of the tenotomy procedure is to remove the force that is primarily responsible for rotation of the distal phalanx and pain associated with the laminar separation.^{1,6} In the original description of the DDF tenotomy, a 3-cm vertical incision was made on the palmar aspect of the flexor tendon sheath at the level of the PIP joint. The surgery was performed with the horse under general anesthesia with the limb surgically prepared and draped to maintain a sterile environment.¹ Subsequently, a DDF tenotomy procedure was developed in which the surgery was performed in the mid-metacarpus with the horse standing.³ Because of the ease of the latter procedure and the fact that it did not require general anesthesia, the mid-metacarpal tenotomy has been widely used in treating horses with laminitis.

In our experience, it is not uncommon to have to repeat the DDF tenotomy when managing refrac-

NOTES

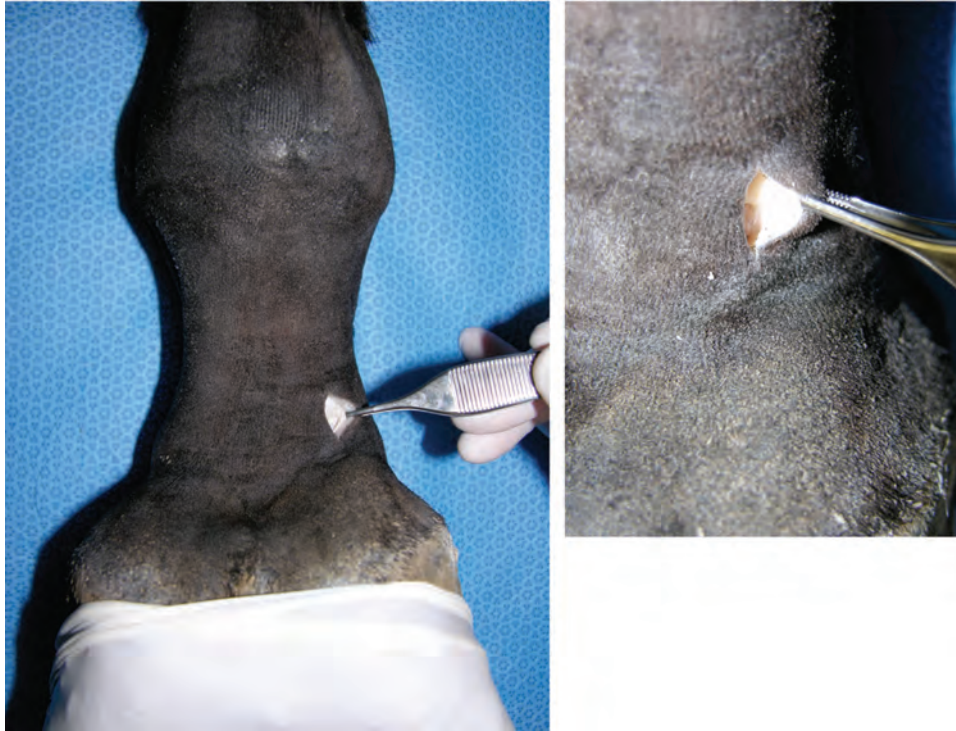

Fig. 1. The 1-cm incision is made between the lateral branch of the SDFT and the DDF tendon on the palmar aspect of the limb just proximal to the collateral cartilage.

tory laminitic cases. Therefore, horses with refractory acute or chronic laminitis typically undergo the tenotomy in the mid-metacarpus as a standing procedure. If necessary, this procedure is followed by a second surgery performed in the mid-metacarpus or at the level of the PIP joint with the horse under general anesthesia. However, we have learned that repeating the mid-metacarpal DDF tenotomy is not always feasible because of the significant scarring that occurs in response to the initial procedure. The presence of this scar tissue may make it difficult to identify the landmarks used to identify the DDF tendon, thereby resulting in inadvertent damage to surrounding soft tissue structures.³ Consequently, it may be advantageous to perform the transection of the DDF tendon at the level of the PIP joint. Because many refractory laminitis cases are managed on the farm or have already been discharged from the veterinary hospital when a second DDF tenotomy is required, it would be beneficial if it were feasible to perform a standing DDF tenotomy at the level of the PIP joint. This surgery would allow a second transection of the DDF tendon with normal anatomical landmarks. It would also eliminate the need for general anesthesia, reduce the cost of the procedure, and bypass the potential stress associated with transporting the horse to the veterinary hospital. The purpose of this manuscript is to describe the results of a cadaver and experimental study on the feasibility of performing a modified standing DDF tenotomy at the level of the PIP joint.

2. Materials and Methods

Cadaver Study

Ten forelimbs, severed at the intercarpal joint, were collected within 24 h of death from five horses of various breeds and ages; the horses were euthanized for various diseases unrelated to the DDF tendon. The distal limb was flexed, and the DDF tendon was palpated within the flexor tendon sheath just proximal to the collateral cartilage. A 1-cm incision was made between the lateral branch of the superficial digital flexor tendon (SDFT) and the DDF tendon on the palmar aspect of the limb just proximal to the collateral cartilage (Fig. 1). Using a Kelly hemostatic forcep, blunt dissection was then used to enter the flexor tendon sheath (Fig. 2). With the distal limb flexed, a straight bistoury knife was introduced into the flexor tendon sheath. After placement of the bistoury knife with the side of the knife lying flat between the DDF tendon and the interior aspect of the flexor tendon sheath, the end of the knife was palpated through the skin to ascertain its correct position deep to the DDF tendon. The cutting edge of the bistoury knife was then turned in an outward direction to engage the DDF tendon (Fig. 3). The distal limb was extended, and the DDF tendon was transected. After the procedure was completed, the tendon sheath was incised to evaluate the ends of the transected DDF tendon and to assess the degree of inadvertent trauma, if any, to the surrounding soft tissue structures (i.e., SDFT branches, flexor

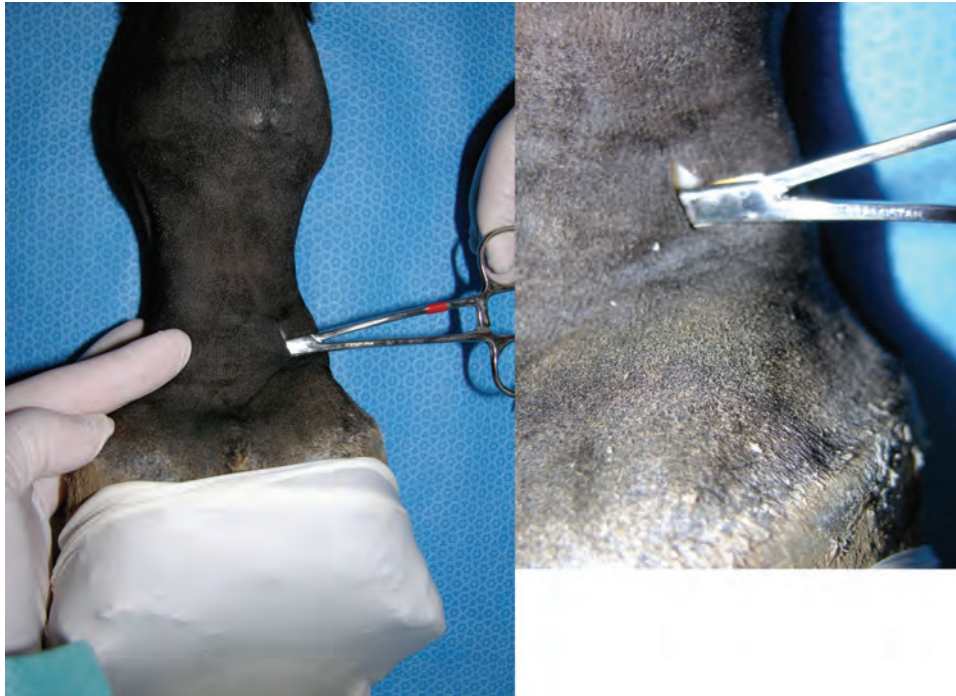


Fig. 2. The Kelly hemostatic forcep is introduced into the flexor tendon sheath using blunt dissection. The Kelly forcep is used to confirm entrance into the tendon sheath and isolate the DDF tendon.

tendon sheath, straight distal sesamoidean ligament, and distal digital annular ligament; Fig. 4).

Experimental Study

Six adult horses (1 mare and 5 geldings, body weight = 425–500 kg, age = 5–10 yr) with normal physical exam findings and no evidence of distal ligament or tendon injury of either forelimb based on ultrasound and radiographic examination were included in this study. One forelimb of each horse was randomly assigned to the surgery group, whereas the contralateral limb was the control.

Surgical Procedure

Before surgery, the foot undergoing the procedure was shod with an extended heel shoe to prevent subluxation of the DIP joint after surgery. The horses were sedated with detomidine HCl^a (0.02 mg/kg, IV), and an abaxial sesamoid nerve block was performed by injecting 3 ml of mepivacaine HCl^b over each palmar digital nerve. The skin was clipped and aseptically prepared with 2% chlorhexidine diacetate.^c Either an assistant or the veterinarian performing the procedure picked up the limb to perform the surgery (Fig. 5). If the veterinarian held the limb, one hand was kept sterile to perform the surgery. A 1-cm incision was made between the lateral branch of the SDFT and the DDF tendon on the palmar aspect of the limb just proximal to the collateral cartilage. Using a Kelly hemostatic forcep, blunt dissection was used to enter the flexor tendon sheath. With the distal limb flexed, a

straight bistoury knife was introduced into the incision. After placement of the bistoury knife with the side of the knife lying flat between the DDF tendon and the interior aspect of the flexor tendon sheath, the end of the knife was palpated through the skin to ascertain its correct position deep to the DDF tendon. The cutting edge of the bistoury knife was then turned in an outward direction to engage the DDF tendon. The distal limb was extended, and the DDF tendon was transected in a palmar direction. Transection of the tendon was confirmed by digital palpation, because ultrasonographic evaluation was limited because of air artifacts in the tendon sheath. The incision was closed with 2–0 polypropylene suture^d in the skin only using a simple interrupted suture pattern. The skin closure was performed either with the limb being held by an assistant or with the horse standing. A sterile pressure bandage was then applied to the distal limb.

Medical Management

Peri-operative antibiotics were administered in the form of procaine penicillin G^e (22,000 IU/kg, q 12 h, IM for 24 h) and gentamicin sulfate^f (6.6 mg/kg, IV before surgery). Peri-operative anti-inflammatory/analgesic therapy consisted of phenylbutazone^g (2.2 mg/kg, q 12 h, IV 72 h and then q 24 h, IV for 72 h). The bandage was changed 48 h after surgery and at 48-h intervals until the skin sutures were removed 14 days after surgery. Each horse was stalled, and

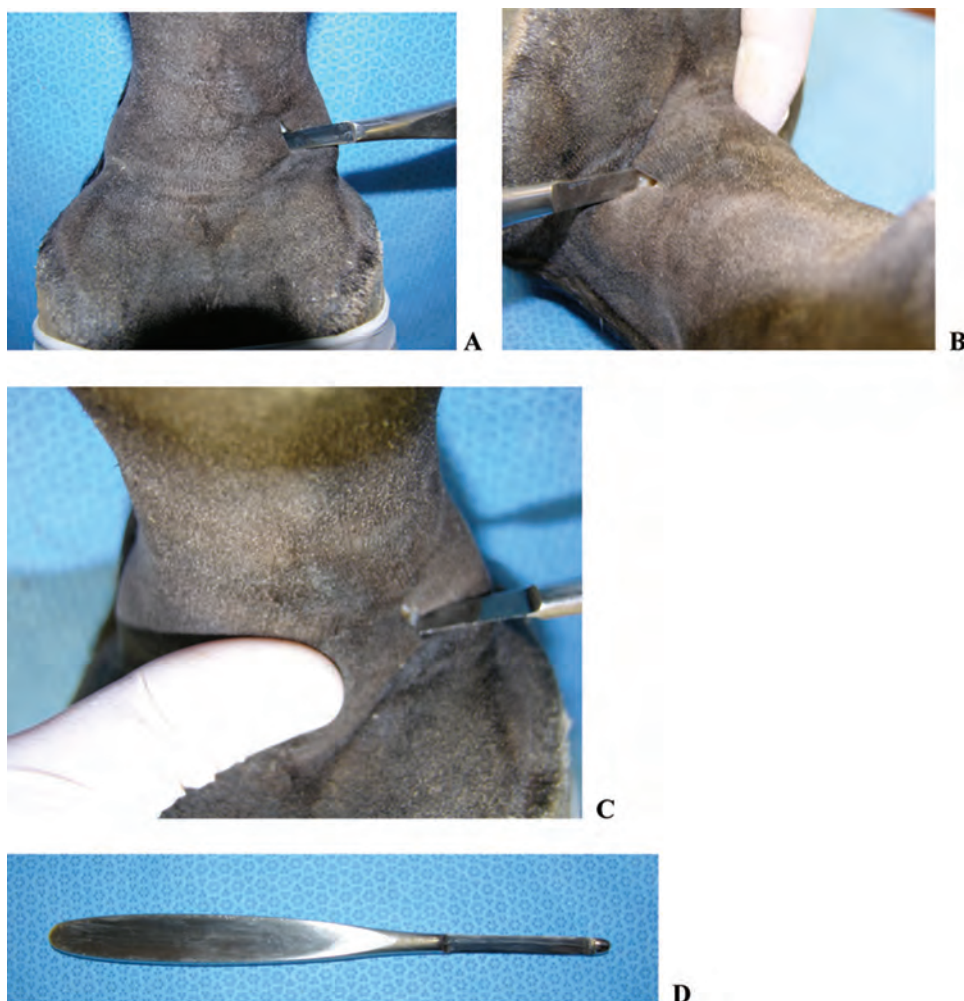


Fig. 3. (A) The bistoury is placed with the side of the knife lying flat between the DDF tendon and the interior aspect of the flexor tendon sheath. The end of the knife was palpated through the skin to ascertain its correct position deep to the DDF tendon. (B) The cutting edge of the bistoury knife was then turned in an outward direction to engage the DDF tendon. (C and D) An example of the straight bistoury knife used in the procedure.

pressure bandages were maintained for 4 wk after the procedure.

Post-Operative Imaging

Ultrasound examinations were performed on days 0 (just before surgery), 2, 15, and 30 of the study using a 10-MHz linear transducer.^h Transverse and longitudinal images were generated at zones 1A–3C and P1A–P2B.⁷ Lesional echogenicity and fiber alignment scores were determined based on a previously described scoring system.⁷ For both parameters, a score of 0 is normal and a score of 3 indicates the presence of 25% or less of normal tissue. The percent lesion (lesion cross-sectional area/total cross-sectional area of the tendon or ligament), total cross-sectional area, lesion cross-sectional area, echogenicity score, and fiber alignment score were determined for each ultrasound image.

Ultrasound evaluation of the DDF tendon was performed 2 days after surgery to confirm transec-

tion of the tendon (Fig. 6). The ultrasonographic examinations on days 0, 15, and 30 of the study were performed to evaluate the following structures: the SDFT and its branches, suspensory ligament and its branches, distal sesamoidean ligaments, DDF tendon, proximal annular ligament, and distal digital annular ligament.

Lateromedial radiographs of the DIP joint were performed 2 days after surgery to evaluate the degree of DIP joint subluxation secondary to transecting the DDF tendon (i.e., palmar displacement of the middle phalanx, width of the DIP joint space, and palmar angle of the distal phalanx). Radiographs of both front feet (two views: lateromedial and straight dorsopalmar views) were taken 30 days after surgery to evaluate hoof growth, medial to lateral balance, and potential development of subluxation of the DIP joint despite corrective shoeing (Fig. 7).

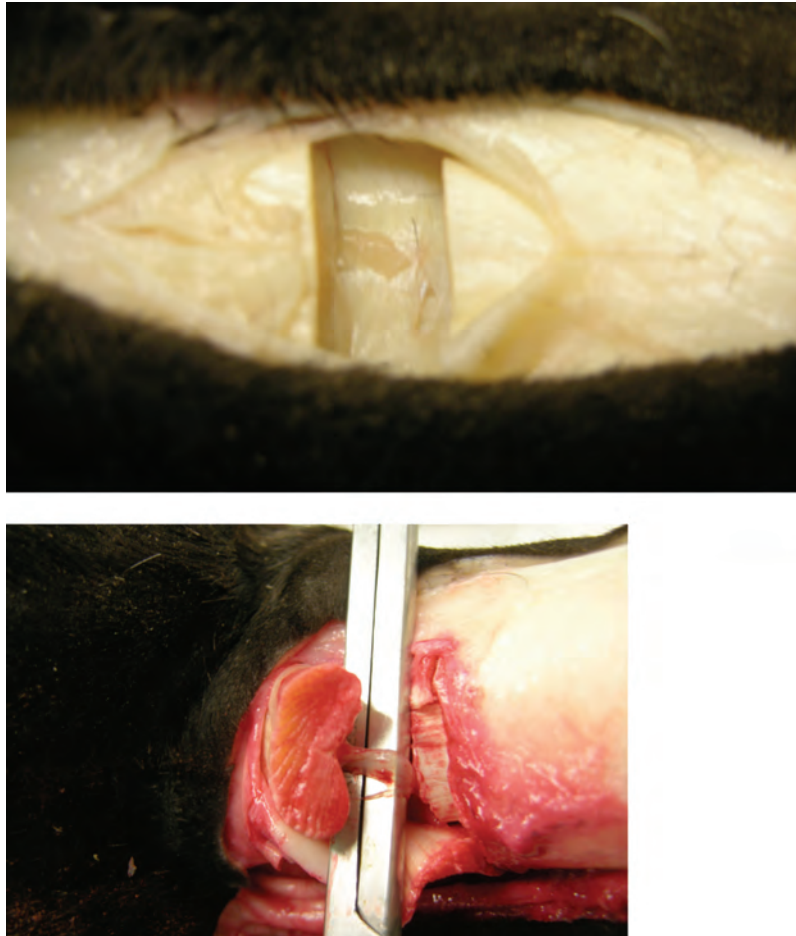


Fig. 4. The modified DDF tenotomy was evaluated in the cadaver study. After the procedure was completed, the flexor tendon sheath was incised to evaluate the transected DDF tendon ends and look for evidence of secondary trauma to the surrounding soft tissue structures (i.e., SDFT branches, flexor tendon sheath, straight distal sesamoidean ligament, and distal digital annular ligament).

3. Results

The DDF tendons included in the cadaver study were successfully transected without secondary trauma to the surrounding soft tissue structures. In the experimental study, the DDF tendons of all of the horses were also successfully transected based on palpation at surgery and the ultrasonographic examination on day 2. The procedures averaged 13 min (10–15 min) in duration from incision to skin closure. All incisions healed without complications, and there was no evidence of post-operative sepsis. The average distance between the transected margins of the DDF tendon was 10 cm (8.5–12 cm). There was no ultrasonographic evidence of inflammation of the surrounding soft tissue structures (i.e., SDFT branches, straight distal sesamoidean ligament, and distal digital annular ligament) at any time point. Although none of the horses had radiographic evidence of DIP joint subluxation on day 2 in the limb that had undergone the tenotomy procedure, there was radiographic evidence of DIP joint subluxation on day 30 in four of

six horses despite corrective shoeing. On day 30, the average palmar angle was -2° ($0-4^\circ$) with an average increase in joint space of 2.75 mm (2–3 mm). The middle phalanx was displaced in a palmar direction in all horses that had subluxation of the DIP joint on day 30. There were no changes in medial to lateral balance or in sole depth when the limbs that had undergone the procedure were compared with the contralateral limb on day 30.

4. Discussion

To the authors' knowledge, a modified standing DDF tenotomy at the level of the PIP joint has not been previously described. Allen et al.¹ first documented the benefit of a DDF tenotomy performed at the PIP joint in treating refractory laminitis cases. As described, that technique was performed with the horse under general anesthesia with the limb surgically prepared and draped to maintain a sterile environment.¹ The disadvantages of that procedure were the need to enter a synovial sheath, size of the incision into the sheath, need for general anesthesia,

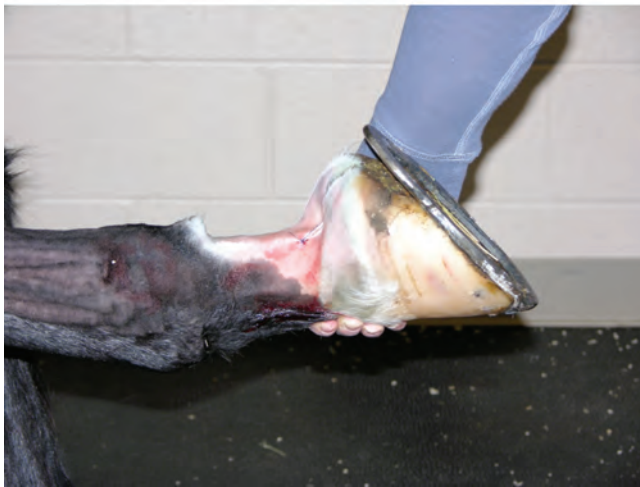
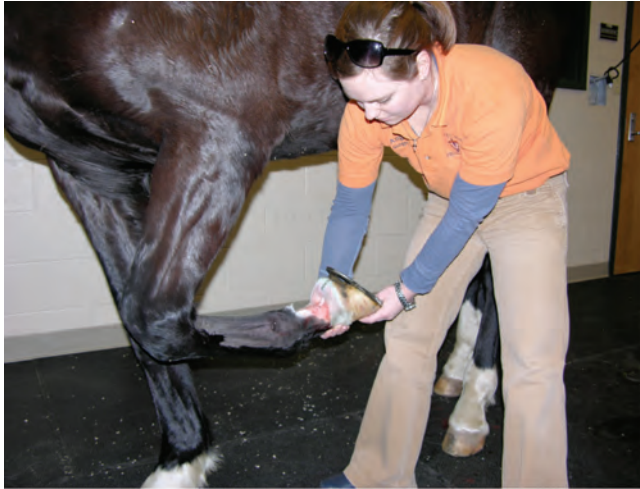
Fig. 5. An assistant holds the limb in flexion during the surgery. The modified DDF tenotomy can be performed with an assistant, or the individual performing the procedure can hold the limb during the surgery.

increased incidence of wound sepsis, DIP joint subluxation, and synovial sinus formation. The need for general anesthesia and a sterile surgical environment required that affected horses be transported to a veterinary hospital for the procedure; these factors translated into increased costs to the owner.

As an alternative, Hunt et al.³ described a mid-metacarpal DDF tenotomy procedure that was also shown to be an effective salvage procedure, because it significantly decreased the pain associated with refractory laminitis. Because this technique could be performed with the horse standing and did not enter a synovial structure, it was more cost-effective and versatile than the original procedure. However, it was reported that DIP joint subluxation and laceration of the medial palmar artery, vein, or nerve were complications of this procedure.³ These complications were most likely caused by the initial description in which a 1-cm skin incision was used.

To address the latter problem, it was recommended that a longer vertical incision be made to better visualize the structures within the surgical site.⁸

The modified DDF tenotomy technique described in this manuscript minimizes the potential complications associated with the previous techniques and has several advantages. For example, none of the horses in the present study developed complications involving either the skin incisions or the flexor tendon sheath, which was a concern with the technique described by Allen et al.¹

The modified DDF tenotomy technique can be performed with the horse standing, thereby minimizing anesthesia-related risks, decreasing the cost to the client, and making the procedure more versatile. The modified technique is minimally invasive, using a 1-cm incision, a blunt dissection to enter the flexor tendon sheath, and a blunted-end bistoury knife to protect the surrounding soft tissue structures. The safety of the modified technique was documented by the ultrasonographic findings on day 15 and 30 of the study. Based on the authors' clinical experience and the reviewed literature,^{3,9} the mid-metacarpal technique allows the transected ends of the DDF tendon to be released by 3–5 cm, whereas the technique in this study released the DDF tendon by 8.5–12 cm. Thus, the modified technique increases the release of the DDF tendon compared with the mid-metacarpal tenotomy.

Two concerns associated with the aforementioned DDF tenotomy techniques are not addressed by the modified technique. The first of these is the fact that four of six horses that underwent the modified tenotomy technique developed subluxation of the DIP joint. These findings are similar to those reported for the previously described techniques; we only provided heel extensions for the horses in the current study, and we realize that more aggressive shoeing will need to be performed in clinical cases. DIP subluxation is a critical issue for the first year after surgery, because it can result in serious DIP degenerative joint disease that may require euthanasia of the animal if not addressed. The subluxation concerns may need to be more aggressively addressed when the tenotomy is performed in the mid-pastern region, because it is likely that the DDF tendon provides a moderate amount of support to the palmar aspect of the DIP joint. Thus, transection of the DDF tendon at that point may possibly cause more instability than when transected at the mid-metacarpus. Because of the degree of subluxation observed in the four horses that underwent the modified procedure, it may be best to shoe the animals with wedges (also true for mid-metacarpal DDF tenotomy) to raise the heels instead of only using trailers on the shoes. The addition of heel wedges commonly allows for increased caudal support of the DIP joint and returns the middle and distal phalanges into alignment more effectively than just providing heel extensions on the shoes. It would be optimal to perform the shoeing immedi-

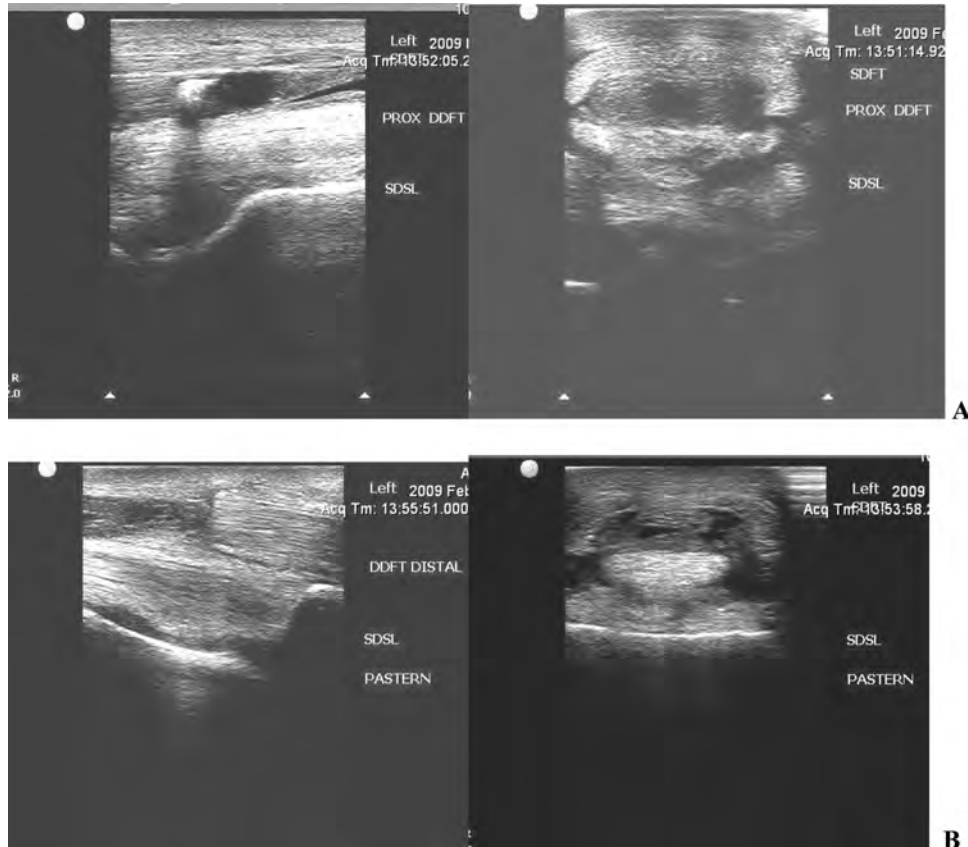


Fig. 6. Ultrasound examinations were performed on days 0 (just before surgery), 2, 15, and 30 of the study. Ultrasound evaluation of the DDF tendon was performed 2 days after surgery to confirm transection of the tendon. The longitudinal and transverse ultrasound images of the (A) proximal and (B) distal transected ends of the DDF tendon are shown.

ately after surgery (while the foot is still under local anesthesia) and to use radiographic assessment at the time of shoeing, because different animals need different degrees of wedging to address subluxation.

Regardless of the type of shoeing used after the DDF tenotomy, it is essential that the heel be aggressively removed before shoeing to “derotate” the distal phalanx in chronic laminitis cases to return the

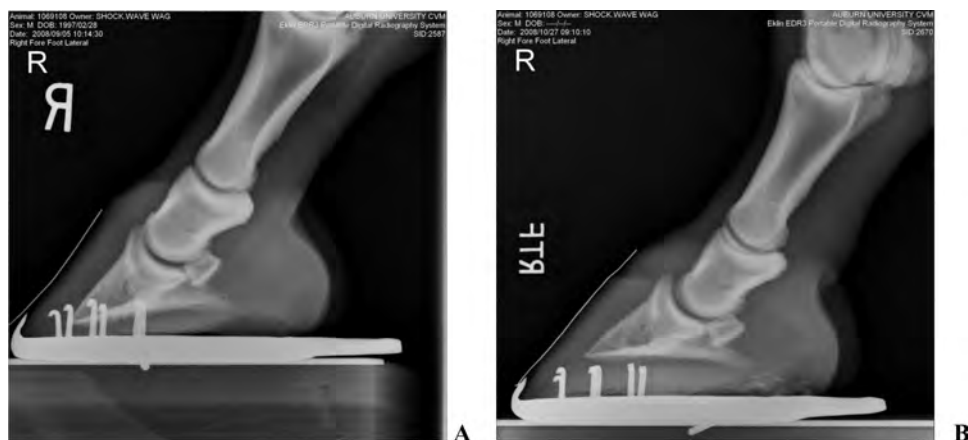


Fig. 7. The lateromedial radiographs of one of the horses in the study. (A) This lateromedial radiograph was performed just before the DDF tenotomy, and (B) this lateromedial radiograph was performed on day 30 of the study. The day-30 radiograph shows evidence of palmar displacement of the middle phalanx, a negative palmar angle of the distal phalanx, and a widening of the distal interphalangeal joint space. These are all findings supportive of subluxation of the distal interphalangeal joint.

relationship between the distal phalanx and the sole to as close to normal as possible.) If this is not accomplished, there is no reason to perform the DDF tenotomy. The practitioner and farrier need to realize that, although it seems counterintuitive to wedge the heel to counteract subluxation after “derotation”/trimming of the heel, the relationship between the distal phalanx and the solar surface is changed by the DDF tenotomy. Therefore, the practitioner and farrier should reexamine and reshoe the horse at ~3–4 wk using radiographic guidance to assess the degree of subluxation. The aim at that time should be to provide only the amount of wedging needed to limit subluxation while allowing maximal separation of the tendon ends before firm adhesions form to the surrounding structures. The corrective shoeing will need to be performed for ~1 yr, and radiographic assessments will need to occur every 2–3 shoeings to facilitate the addressing of the degree of DIP subluxation and the position of the distal phalanx (i.e., rotation).

The second concern of the modified technique is the need to enter a synovial sheath at the time of surgery. Like the other techniques, this could lead to sepsis of a synovial structure if asepsis is not strictly followed. In the current study, none of these potential complications with the flexor tendon sheath were noted.

Refractory or chronic laminitic cases are difficult to manage, and in many cases, they require repeated DDF tenotomies over the life of the horse to minimize complications and maintain a relative level of comfort. The mid-metacarpal technique is most commonly used, but an alternative approach is needed when multiple procedures have been performed in this region or if significant fibrosis in the area makes this approach difficult. Based on the findings of the current study, the modified standing DDF tenotomy at the level of the PIP joint is an alternative approach to repeated mid-metacarpal DDF tenotomies. However, one must recognize

that strict attention must be paid to the development of DIP subluxation for at least 1 yr after surgery.

References and Footnotes

1. Allen D Jr, White NA II, Foerner JF, et al. Surgical management of chronic laminitis in horses: 13 cases (1983–1985). *J Am Vet Med Assoc* 1986;189:1604–1606.
 2. Pollitt CC. Medical therapy of laminitis. In: Dyson SJ, ed. *Diagnosis and management of lameness in the horse*, 1st ed. St. Louis, MO: W. B. Saunders Co., 2003;329–331.
 3. Hunt RJ, Allen D, Baxter GM, et al. Mid-metacarpal deep digital flexor tenotomy in the management of refractory laminitis in horses. *Vet Surg* 1991;20:15–20.
 4. Eastman TG, Honnas CM, Hague BA, et al. Deep digital flexor tenotomy as a treatment for chronic laminitis in horses: 35 cases (1988–1997). *J Am Vet Med Assoc* 1999;214:517–519.
 5. Nickles FA. Hoof care of a laminitic horse. In: Dyson SJ, ed. *Diagnosis and management of lameness in the horse*, 1st ed. St. Louis, MO: W. B. Saunders Co., 2003;329–331.
 6. Coffman JR, Johnson JH, Finocchio EJ, et al. Biomechanics of pedal rotation in equine laminitis. *J Am Vet Med Assoc* 1970;156:219–221.
 7. Rantanen NW, Jorgensen JS, Genovese RL. Ultrasonographic valuation of the equine limb: technique. In: Dyson SJ, ed. *Diagnosis and management of lameness in the horse*, 1st ed. St. Louis, MO: W. B. Saunders Co., 2003; 166–188.
 8. Turner AS, McIlwraith CW. Deep digital flexor tenotomy. In: Turner AS, McIlwraith CW, eds. *Techniques in large animal surgery*. Philadelphia: Lea & Febiger, 1989;153–155.
 9. Hunt RJ. Deep digital flexor tenotomy for managing laminitis. In: Dyson SJ, ed. *Diagnosis and management of lameness in the horse*, 1st ed. St. Louis, MO: W. B. Saunders Co., 2003;335–338.
- ^aDetomidine HCl, Pfizer Animal Health, Exton, PA 19341.
^bMepivacaine HCl, Pharmacia & Upjohn Co., Division of Pfizer, New York, NY 10017.
^cNolvasan, Fort Dodge Animal Health, Fort Dodge, IA 50501.
^d2–0 Prolene, Ethicon, Somerville, NJ 08876.
^eProcaine Penicillin G, Butler Animal Health Supply, Dublin, OH 43017.
^fGentamicin sulfate, Butler Animal Health Supply, Dublin, OH 43017.
^gPhenylbutazone, Schering-Plough Animal Health Corp., Union, NJ 07083.
^hPhillips HD11XE, Phillips Medical Systems, Bothell, WA 98021–8431.