

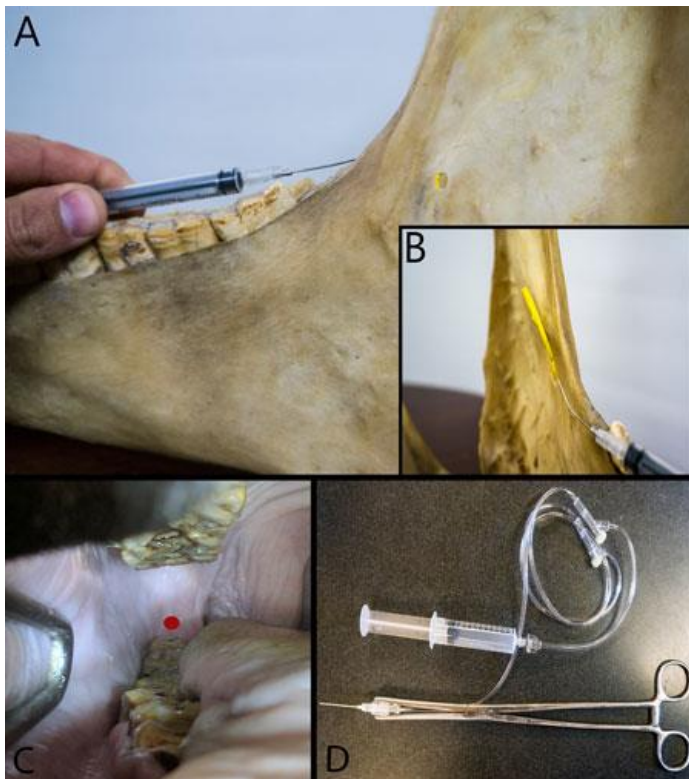
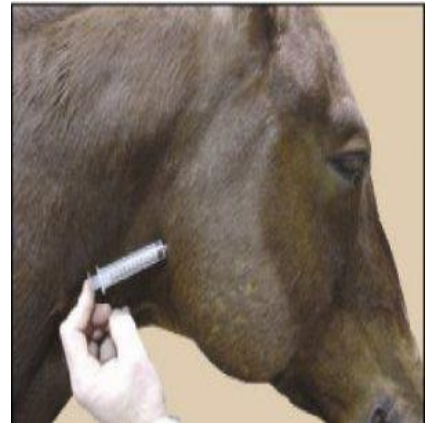
Mandibular Nerve Block /Inferior alveolar nerve block

Nerve: The inferior alveolar nerve. Branches from this nerve supply the teeth before it exits via the mental foramen.

Location: Palpate and draw a line along the buccal edge of the upper dental arcade. Extend this line to the back of the mandible. The foramen should be approximately 3.5 inches from the back edge of the mandible along this line in an average size horse (2).

To Block:

Technique one (blind technique)- Extended the head of the horse to gain better access to the back of the mandible and locate the foramen where the needle would be inserted on the medial surface of the mandible. Using a long (8- to 10-in) 18- to 22-ga spinal needle direct it rostrally from the back edge of the mandible close to the mandibular foramen. Inject 15 to 30 ml of local anaesthetic. It is better to make an error on the high side of the foramen than below the foramen.



Technique two (intraoral approach)- A 12-in-long locking clamp pliers is used to secure a 20-ga, 1.5-in (3.8-cm) needle bent 20 to 30 degrees attached to an extension set. The needle is inserted in the mucosa on the medial aspect of the mandible caudal and above the table surface of the third mandibular molar and lateral to the palate. Inject 5 to 7 ml of local anaesthetic.

Use: Indicated in the use for blocking the inferior alveolar nerve for extraction of premolars and molars in the lower arcade, debridement of deep periodontal pocketing associated with diastemas, debridement of mandibular drainage tracks, and wire fixation of rostrally located mandibular fractures in standing horses (2).

The nerve block is difficult to perform. Complications are more common with the blind technique and include:

1. Block failure from improper placement.
2. Hematoma or abscess formation.
3. Horse-inflicted trauma to the tongue from inadvertent blocking of the lingual nerve. (Use a mouth gag until the local anaesthetic agent has fully worn off.)

References

1. Equine Dental Local Anaesthesia [Internet]. Academy of Equine Dentistry Blog. 2010 [cited 28 October 2018]. Available from: <https://academyofequinedentistry.wordpress.com/2010/03/23/equine-dental-local-anesthesia/>
2. A guide to regional analgesia of the head in equine patients [Internet]. dvm360.com. 2018 [cited 28 October 2018]. Available from: <http://veterinarynews.dvm360.com/guide-regional-analgesia-head-equine-patients?pageID=4>