



PROFESSOR SIR FREDERICK HOBDAY, C.M.G., HONORARY  
VETERINARY SURGEON TO H.M. THE KING

*This striking Court-uniform portrait in oils by John Hassall, R.I., was presented to Sir Frederick by the Duke of Portland, on behalf of the subscribers to the "Hobday Portrait Fund," at the Connaught Rooms, Great Queen Street, London, W.C., on Thursday last. Professor Hobday, Principal and Dean and Professor of Surgery at the Royal Veterinary College, London, is best known in hunting and riding circles for his throat operation for "roaring" in horses. His outstanding public work has been in connection with the rebuilding and organisation of the College.*

*To my distinguished Colleague & Friend  
Lupinus King  
With kindest regards  
Mike Ince*

# THE HOBDAY SURGERY

## Over View of some Procedures

Ventriculectomy, or sacculectomy, consists of the removal of the mucous membrane lining the laryngeal ventricle. This technique is accomplished by performing a laryngotomy through the cricoid membrane. Ventriculocordectomy is essentially a sacculectomy with the additional removal of a small wedge of tissue from the leading edge of the vocal fold. Ventriculocordectomy is indicated for horses affected by vocal fold collapse and some show and draft horses with laryngeal hemiplegia. The technique of laryngotomy described here is also used for partial resection of the soft palate, arytenoidectomy, and the surgical treatment of epiglottic entrapment, pharyngeal cysts, or lymphoid hyperplasia.

Ventriculectomy and ventriculocordectomy are not indicated alone for treatment of laryngeal hemiplegia in sport horses or racehorses, because they will not produce abduction of the arytenoid cartilages and alleviate airway obstruction in these horses. These procedures are, however, appropriate in animals in which the arytenoid cartilage is not adducted beyond the normal resting position, so the larynx appears symmetric at rest. For some show horses, these treatments will provide satisfactory reduction of respiratory noise by reducing soft tissue collapse during exercise.



# Over View of some Procedures

Laryngoplasty is used when endoscopic examination shows that the arytenoid cartilage is displaced medially from the resting position. In these cases, ventriculectomy alone will not provide sufficient abduction of the vocal cord. Ventriculocordectomy can be used as the sole treatment for laryngeal paresis in cases with low grade recurrent laryngeal neuropathy.

Laser-assisted ventriculectomy and ventriculocordectomy, either alone or in conjunction with laryngoplasty, are indicated for treatment of specific cases of laryngeal hemiplegia, as previously described. Although laser assisted surgical techniques are considered advanced, they will be discussed here because they are important alternatives to many of the traditionally performed upper respiratory surgical techniques. This technique is usually performed using a neodymium:yttrium garnet or diode laser trans-endoscopically through an oral approach or by performing a laryngotomy. The trans-endoscopic laser guided technique does not require a laryngotomy, and therefore it reduces anesthesia and convalescence time.

Laser vocal cordectomy has been described as a potential treatment for laryngeal hemiplegia, but it has not been shown to reduce respiratory noise as effectively as ventriculocordectomy.

# Equine Anaesthesia for Laryngeal Surgery

Before laryngeal surgery, horses are fasted for 8 to 12 hours. Preoperative and perioperative nonsteroidal anti-inflammatory medication (phenylbutazone) and broadspectrum antibiotics are indicated for these surgeries for a period of 5 days. The anesthetist should be aware that some horses with a longstanding unilateral arytenoid paralysis can be difficult to intubate with a standard-size tube, and a smaller-diameter tube should be available. In unique situations, the horse may be first placed in dorsal recumbency to allow for visual and digital inspection of the arytenoid cartilages through a laryngotomy. This approach might be taken when endoscopic observations suggest the presence of subtle arytenoid chondritis or when there has been previous laryngeal surgery.



## VENTRICULECTOMY (SACCULECTOMY)

Ventriculectomy (unilateral or bilateral) refers to the removal of the mucosal lining of the laryngeal ventricle located caudal to the vocal fold. It is usually performed to eliminate noise and can have some beneficial effects on performance. Because it does not produce abduction of the arytenoid cartilage, ventriculectomy is not recommended as a sole procedure for racing horses affected with laryngeal hemiplegia. However, it reduces soft tissue collapse during exercise and can be quite successful if performed on certain show horses. Because the complication rates of laryngoplasty (e.g., failure, anesthetic problems, coughing) approach 30% in draft horses, the author prefers to perform a bilateral ventriculectomy in the standing horse.

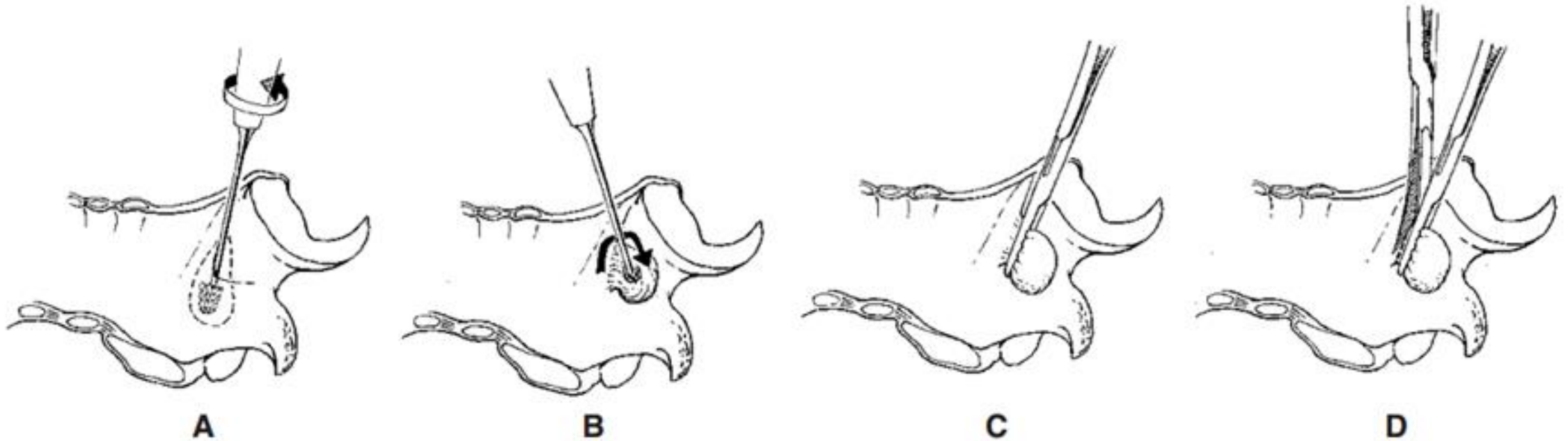
- The horse is placed in the stocks and sedated with loading doses of detomidine (4 mg IV) and butorphanol (10 mg IV).
- After starting a detomidine drip (14 mg added to 250 mL of saline) to effect (approximately 2 drops per second for 15 minutes, 1 drop per second for 15 minutes, and so on, as the effect is highly variable), the horse's head is elevated and the laryngotomy site is prepared.
- Local anesthetic is injected underneath the skin in the area of the laryngotomy approach.

## VENTRICULECTOMY (SACCULECTOMY)

- After the final preparation, a 10-cm incision is made on the ventral midline, centered over the junction of the horizontal and vertical rami of the mandible. The paired sternothyrohyoideus muscles are separated on the midline and the characteristic V in the thyroid cartilages is palpated.
- Laryngotomy is performed with a #10 scalpel blade. A burr is introduced into the ventricle to its depth and twisted, engaging the mucosa in the projections on the burr (Fig. 44-9, A and B).
- Occasionally, the ventricle is so large that it is necessary for the operator to press on the laminar portion of the arytenoid cartilage to enable the burr to engage the mucosa of these large saccules at their apex.
- The burr is then withdrawn slowly from the ventricle, everting the attached saccule. Swallowing usually occurs during this procedure and helps evert the saccule. A large hemostat is placed across the everted saccule proximal to the head of the burr (see Fig. 44-9, C), and with traction on the clamp, a second clamp is placed behind it.
- With digital pressure on the opening of the ventricle, the entire saccule is everted and then excised with Metzenbaum scissors (see Fig. 44-9, D).
- The same procedure is repeated on the opposite ventricle, which is allowed to heal along with the laryngotomy incision by second intention.



# VENTRICULECTOMY (SACCULECTOMY)



**Figure 44-9.** Schematic illustration of the ventriculectomy technique with the horse in dorsal recumbency. **A**, The "roaring" burr is placed into the laryngeal ventricle and rotated so that the head of the burr engages the mucosa of the laryngeal sacculus. **B**, Once the sacculus is firmly engaged, it is everted into the lumen of the larynx by steadily pulling on the burr. **C**, A large hemostat is placed across the sacculus immediately adjacent to the vocal fold, and the burr is removed. **D**, The sacculus is completely excised using Metzenbaum scissors adjacent to the hemostat.

# Ventriculectomy Postoperative management

- It is important that the horses receive loading doses of antibiotics any time the respiratory tract is invaded. Anti-inflammatory therapy is an important component of minimally invasive upper respiratory tract surgery. Phenylbutazone (4.4 mg/kg, IV) or flunixin meglumine (1.1 mg/kg, IV) is given immediately before surgery. Horses needing only minimal continued anti-inflammatory support are subsequently given phenylbutazone (2.2 mg/kg PO, twice a day for 7 days); alternatively, dexamethasone powder (0.022 mg/kg) is given orally once daily in the morning feed for 3 consecutive days, day 4 is skipped, and the same dosage is then given on the 5th postoperative day.
- If a longer course of corticosteroid therapy is deemed necessary, 0.9 mg/kg of prednisone is given orally starting the day after surgery once daily in the morning feed for 7 days. The same dosage is then given every other day for three treatments. The dosage is subsequently reduced to 0.45 mg/kg, given every other day for three treatments. Topical administration of a pharyngeal medication, a mixture of nitrofurazone (Furacin) or pediatric trimethoprim sulfa (oral preparation), dimethyl sulfoxide, glycerin, and prednisolone also appears to be beneficial. A no. 10 French catheter is advanced along the floor of the nasal passage into the nasal pharynx, and 10 to 15 mL of the solution is sprayed slowly through this catheter at 12-hour intervals for 7 days.
- The horse is restricted to hand-walking exercise for the 1st week after surgery. After this time, an endoscopic re-examination is performed to assess wound healing and to determine if the horse can return to paddock exercise or if additional rest and anti-inflammatory medication are necessary. The horse should not be returned to training for 90 days.



# VENTRICULOCORDECTOMY

Ventriculocordecotomy refers to the removal of the mucosal lining of the laryngeal ventricle as described earlier, as well as to removal of a crescent-shaped wedge of tissue from the leading edge of the vocal fold. Again, because this technique does not produce abduction of the arytenoid cartilage, its use as a sole procedure for most racing horses with laryngeal hemiplegia running over long distances is not recommended. However, its use to reduce noise in sport horses has been established. It has also been documented that there is some reduction in airway obstruction using this technique. Therefore, case selection could include the following:

- Sport horses with grade 4 laryngeal movements where the primary complaint is respiratory noise and exercise intolerance is not a feature (hunters and other show horses)
- Race horses with grade 3 laryngeal movements that do not experience arytenoid collapse during high-speed exercise but do experience vocal fold collapse
- Race horses that have had a laryngoplasty and still experience vocal fold collapse during high-speed exercise. (Caution must be used in performing a ventriculocordecotomy in racehorses that have had a laryngoplasty where noise is a complaint, because noise cannot be correlated with upper airway obstruction.)

# VENTRICULOCORDECTOMY

## Anesthesia and Surgical Preparation

Laryngotomy and ventriculectomy may be performed with the horse under general anesthesia and in dorsal recumbency or with the standing animal sedated and injected with local analgesic at the surgical site. Prior to surgery (ideally, 4 hours prior), the patient is given 2 g of phenylbutazone intravenously to minimize postoperative laryngeal edema. The surgical area at the caudal aspect of the mandible is clipped and prepared aseptically (Figure 11.2A).

To perform the endoscopically guided ventriculectomy, the horse is placed in standing stocks and sedated with 0.3 mg xylazine HCl. A jugular catheter is placed and a continuous infusion of 20 mg detomidine in 1 L polyionic fluids is used to maintain sedation. A flexible endoscope is passed nasally, and 20 ml of 2% carbocaine is used to bathe the surgery area.



# VENTRICULOCORDECTOMY

- A skin incision centered at the caudal aspect of the mandible, approximately 10 cm long, is made from the surface of the cricoid cartilage to beyond the junction of the thyroid cartilages (Figure 11.2A). In some instances, the triangular depression between the thyroid cartilages and cricoid cartilage can be felt before the skin incision is made. When this is not possible, the central area of the skin incision is located by placing a horizontal line across the area where the rami of the mandible merge with the neck.
- The skin incision exposes the midline between the sternothyrohyoideus muscles, which are separated with scissors to expose the cricothyroid membrane. After initial separation with scissors, the muscles may be retracted digitally for the length of the skin incision. The cricothyroid membrane is cleared of adipose tissue, and at this stage, it may be necessary to ligate a small vein that commonly is present in the surgical site.
- The cricothyroid membrane is then incised, commencing with a stab incision, to penetrate the laryngeal mucosa (Figure 11.2B). The incision is then extended longitudinally from the cricoid cartilage caudad to the junction of the thyroid cartilages cranially. The wings of the thyroid cartilages are retracted with a self-retaining retractor (Gelpi, Weitlaner, or Hobday's roaring retractor).

# VENTRICULOCORDECTOMY

- If a small-diameter, cuffed endotracheal tube is used, ventriculectomy may be performed with the endotracheal tube in place; otherwise, removal of the tube will be necessary for identification of the laryngeal saccule and ventriculectomy.
- The laryngeal ventricle is identified by sliding the index finger craniad off the edge of the vocal cord and turning the finger laterad and downward toward the base of the ear to enter the ventricle. The laryngeal bur is passed into the ventricle as deeply as possible and twisted to grasp the mucosa (Figure 11.2C). A sagittal section of the larynx showing the location of the laryngeal ventricle is illustrated in Figure 11.2D.
- When the operator believes that the mucosa is engaged in the bur, the bur is carefully withdrawn from the ventricle by everting the ventricular mucosa (Figure 11.2E). At this stage, it is advisable to place a pair of forceps on the everted mucosa to avoid tearing or slippage as the mucosa is fully retracted. The forceps are attached to the mucosa, the bur is untwisted and removed, and the ventricular saccule is completely everted using traction.
- With retraction maintained by Ochsner forceps or a similar instrument placed across the saccule, the everted mucous membrane is resected with scissors as close to the base as possible without damaging associated cartilage (Figure 11.2F).
- It is common to perform the ventriculectomy bilaterally, but the clinical problem is usually associated with the left side. Following excision of the ventricle, any tags of remaining mucous membrane are removed.



# VENTRICULOCORDECTOMY

- To perform a ventriculocordectomy, an additional 2-cm long and 2-mm wide crescent-shaped wedge is excised from the leading edge of the adjacent vocal fold after performing ventriculectomy. The abaxial edge of the vocal fold and the axial border of the ventricle may be opposed and sutured using 2-0 PDS. This serves to limit haemorrhage and lessen cicatrix formation and redundant tissue folds. Many surgeons do not close the mucosa.
- The cricothyroid membrane is closed using 3-0 polyglytone 6211 (Caprosyn). The rest of the laryngotomy incision is not sutured, but is left open, because the respiratory tract mucosa cannot be aseptically prepared and contamination of the incision can occur with subsequent infection and abscessation as potential problems. The laryngotomy wounds heal satisfactorily by secondary intention; therefore, suturing this wound is not considered justifiable. Conversely, a tracheostomy tube can remain in the laryngotomy site while the horse recovers from anesthesia.

# VENTRICULOCORDECTOMY

## Laser Ventriculectomy/Ventriculocordecotomy

- The laser fiber is placed through the biopsy channel of the flexible endoscope and the endoscope placed into the nasal passage of the horse (Figure 11.2G). The laser is set at 15 watts, and the laser fiber extended through the end of the scope. The laser should never be fired if the fiber tip is not easily seen on the monitor. Because the fiber lasers create significant collateral damage, only the surface mucosa need be ablated (Figure 11.2H).
- In many instances, both ventricles are ablated along with the vocal cords to minimize noise after surgery.
- Care should be taken to avoid lasering the most ventral commissure of the vocal folds to reduce the chance of cicatrix formation. There is no laryngotomy incision to care for using this approach.



# VENTRICULOCORDECTOMY

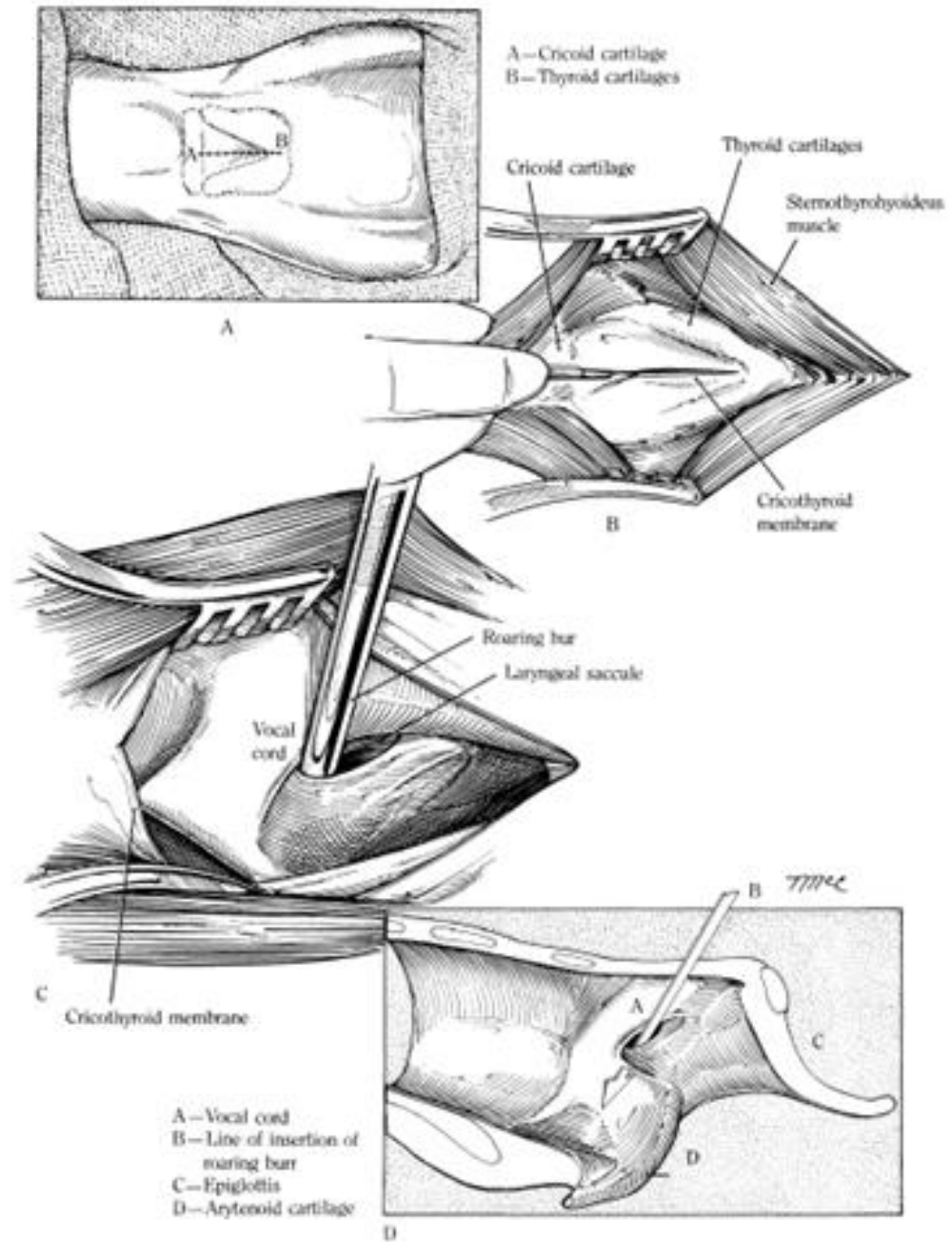
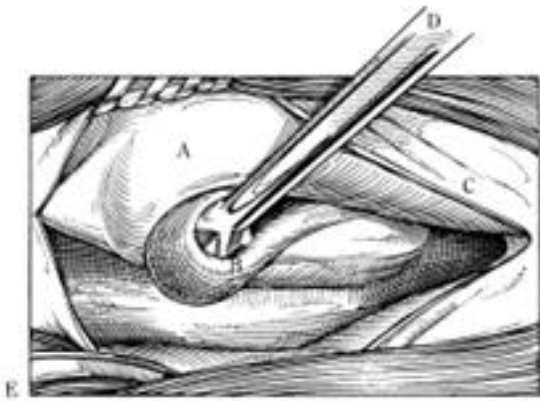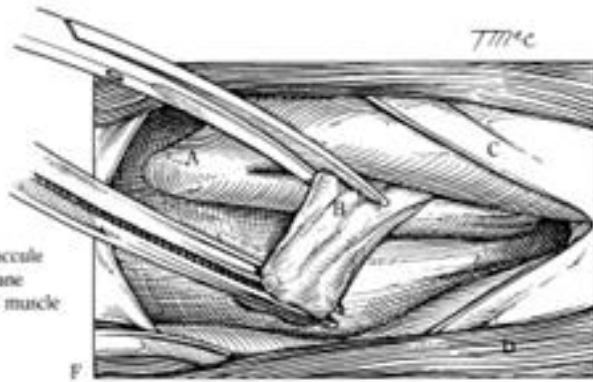


Fig. 11.2. A-H. Laryngotomy, laryngeal ventriculectomy, laser ventriculocordectomy.

# VENTRICULOCORDECTOMY



A—Vocal cord  
B—Eversion of laryngeal saccule  
C—Cricothyroid membrane  
D—Roaring bar



A—Vocal cord  
B—Everted laryngeal saccule  
C—Cricothyroid membrane  
D—Stenothyrohyoideus muscle

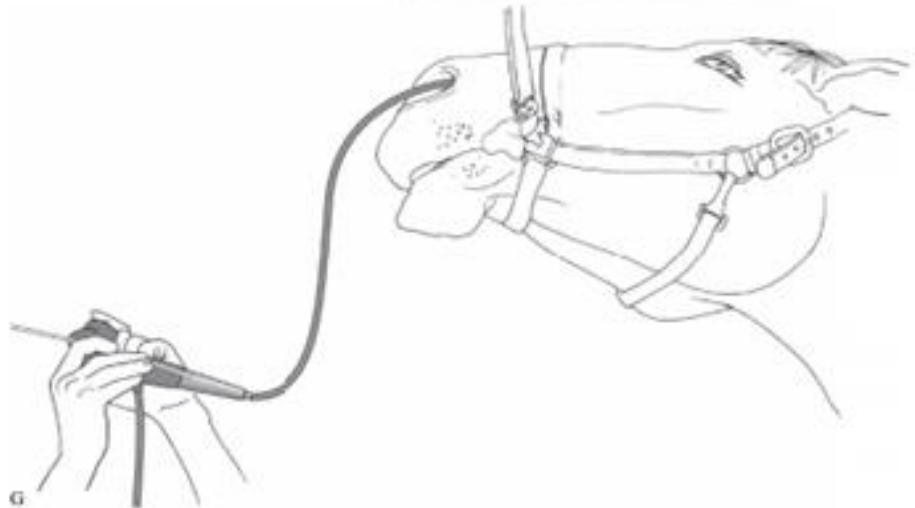
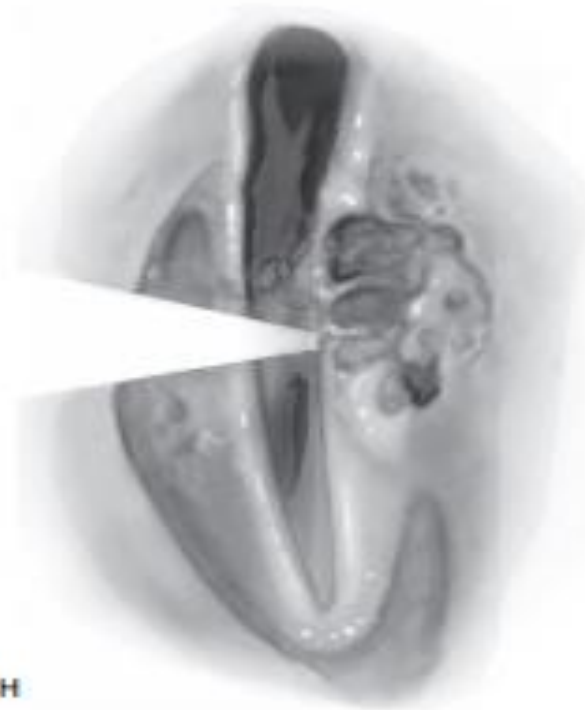


Fig. 11.2. Continued.



H

Fig. 11.2. Continued.



# VENTRICULOCORDECTOMY

## Postoperative Management

Antibiotics are not administered routinely. The laryngotomy wound is cleaned twice daily. The animal is confined for the 2–3 weeks it takes for the wound to heal. After this period, the horse is hand-walked. The horse may be put back to work 8 weeks following surgery. The tracheostomy tube is usually left in the laryngotomy opening until the patient recovers from anesthesia.

If there is undue trauma during surgery—more likely with some of the more involved procedures performed by a laryngotomy approach—it may be advisable to leave the tracheostomy tube in place in case laryngeal edema develops. Do not perform a separate tracheostomy without a specific, critical indication.

# VENTRICULOCORDECTOMY

## Prognosis

Ventriculectomy or ventriculocordecotomy performed alone has less risk of complications than these procedures performed in conjunction with laryngoplasty.

A study in draft horses showed that ventriculectomy alone significantly improved athletic performance to a level deemed satisfactory by owners in 87% of these horses. In one report, 86% of owners considered the surgery worthwhile, 3% did not consider it worthwhile, and 11% were unsure.



# VENTRICULOCORDECTOMY

## Complications


- Inflammation and infection of the open laryngotomy incision rarely cause a problem that cannot be resolved by establishing good drainage followed by applying a topical antimicrobial ointment. A clostridial infection at the laryngotomy site, however, can be catastrophic or even fatal. Within a 24-hour period after surgery, a clostridial infection can produce tremendous swelling of the head and neck that results in a massive tissue slough. The use of perioperative penicillin may avoid such an infection, and if it does occur, early recognition and prompt treatment with intravenous penicillin is critical.
- Rarely, excessive granulation tissue forms in the ventricles after sacculotomy. This problem usually resolves with time and the application of anti-inflammatory sprays.
- Complications associated with laser ventriculectomy in general, horses will ingest food and water without apparent discomfort in 6 hours postoperatively. Thermal damage to surrounding tissue, inadequate removal of ventricular mucosa due to poor visualization, excessive tissue sloughing, mucocele formation, laser burns to the contralateral vocal cord, and arytenoid cartilage necrosis have been documented following laser ventriculocordecotomy, however. Complete healing of the surgical site was affirmed by endoscopic evaluation at 47 days postoperatively.
- A histologic study showed that there was no collateral damage to the laryngeal cartilage when using a diode laser in contact fashion at 20 watts.

# VENTRICULOCORDECTOMY

## Special Considerations

- Attempts to develop a technique for laser ventriculocordectomy in standing horses have not been successful.<sup>50</sup> When a neodymium:yttrium aluminum garnet (Nd:YAG) laser was used in noncontact fashion via a nasal approach, or in contact fashion via an oral approach, viable mucosa of the ventricle remained after surgery, sometimes resulting in a mucocele. Additionally, although laser vocal cordectomy alone is used clinically, a recent study showed that laser vocal cordectomy does not effectively reduce the noise associated with laryngeal hemiplegia by 120 days after surgery.
- Therefore, refinements in surgical technique are required before laser ventriculocordectomy can be used with confidence to obviate noise production in horses affected with laryngeal hemiplegia.





# Saddle Up!

by Sir Frederick Hobday