

Bovine rumenotomy: Comparison of four surgical techniques

Seifollah N. Dehghani, Amir M. Ghahrdani

Abstract

Rumenotomy in cattle is a routine procedure for treatment and diagnostic purposes. A comparative study of different rumenotomy techniques is lacking in the veterinary literature. Four rumenotomy techniques were compared in 20 cattle: skin suture fixation, Weingarh's ring, stay suture, and skin clamp fixation. Results indicated that skin suture fixation was superior to Weingarh's ring and the stay suture techniques. Skin clamp fixation was comparable with skin suturing and required a shorter operative time. Rumenotomy using the stay suture technique was followed by postoperative inflammatory complications, as indicated by significant ($P < 0.05$) increases in mean body temperature and total white blood cell counts of 39.3 , $s = 0.56^\circ\text{C}$ and 12.6×10^9 , $s = 1.57 \times 10^9/\text{L}$, respectively, on day 4. Therefore, rumenotomy using the skin clamp fixation technique could be considered as an alternative to the more commonly used skin suture fixation technique.

Résumé

Comparaison de quatre techniques chirurgicales de rumenotomie chez le bovin

La rumenotomie est une procédure chirurgicale courante utilisée comme moyen de diagnostic et de façon thérapeutique. Toutefois, la documentation ne compte aucune étude comparative de l'efficacité des différentes techniques chirurgicales. Les auteurs ont évalué quatre méthodes de rumenotomie utilisées sur 20 animaux : la fixation de la suture du rumen à la peau, l'anneau de Weingarh, la suture de rétention et la fixation du rumen à la peau par des agrafes. Les résultats montrent que la fixation de la suture du rumen à la peau est supérieure à la méthode de Weingarh et aux sutures de rétention. De plus, la technique de fixation par des agrafes se compare à celle de la suture du rumen à la peau tout en diminuant le temps chirurgical. Une réaction inflammatoire postopératoire a été notée lors de rumenotomie combinée à une technique de suture de rétention. Dans ces cas, il y avait une élévation significative ($p < 0,05$) de la température corporelle

moyenne et une augmentation significative du compte leucocytaire au quatrième jour, soit respectivement $39,3$, $S = 0,56^\circ\text{C}$ et $12,6 \times 10^9$, $S = 1,57 \times 10^9/\text{L}$. Les auteurs concluent que lors de rumenotomie, la méthode de fixation du rumen à la peau au moyen d'agrafes peut être une alternative à la technique plus conventionnelle de suturer le rumen à la peau.

(Traduit par docteure Thérèse Lanthier)

Can Vet J 1995; 36: 693-697

Introduction

Rumenotomy is a routine procedure for many diseases in cattle, such as, traumatic reticuloperitonitis; ingestion of toxic plants, chemicals, spoiled roughage, or fetal membranes after parturition; acute and recurrent bloat; placement of a temporary or permanent rumen cannula to relieve bloat; creation of a permanent rumen fistula; and impactions (1). Other reasons include ingestion of materials, such as, baling twine or plastic bags that are obstructing the reticulo-omasal orifice, foreign bodies lodged in the distal esophagus, and rumen overload (2). Rumenotomy can also be used for the diagnosis of intraruminal diseases other than those associated with foreign bodies (3). The recommended techniques for rumenotomy are suturing the rumen to the skin, prior to rumenotomy (2), or using fixation devices, such as, a Weingarh's ring (4). An alternative technique for rumenotomy involves the use of stay sutures. The technique selected depends on the personal preference of the veterinarian. A comparative study of these techniques has not been made. The purpose of this study was to compare the available rumenotomy techniques and describe the intraoperative and postoperative complications. Also, a new technique, using towel clamps, is introduced and compared with the other techniques.

Materials and methods

Twenty mixed Iranian cattle of both sexes, weighing between 200 and 415 kg (mean 304.5, $s = 63.5$ kg) and aged between 1.5 and 4 y (mean 2.7, $s = 0.8$ y), destined for slaughter were used. Animals were fed identical rations and kept under identical conditions. Prior to starting the study, a thorough physical examination was carried out, including collection of venous blood for total and differential white blood cell (WBC) counts. The animals were randomly allocated to 4 groups of 5 and deprived of food for 24 h and water for 12 h before the

Department of Veterinary Surgery, School of Veterinary Medicine, Shiraz University, 71365 Shiraz, Iran.

Funded by Shiraz University research program.

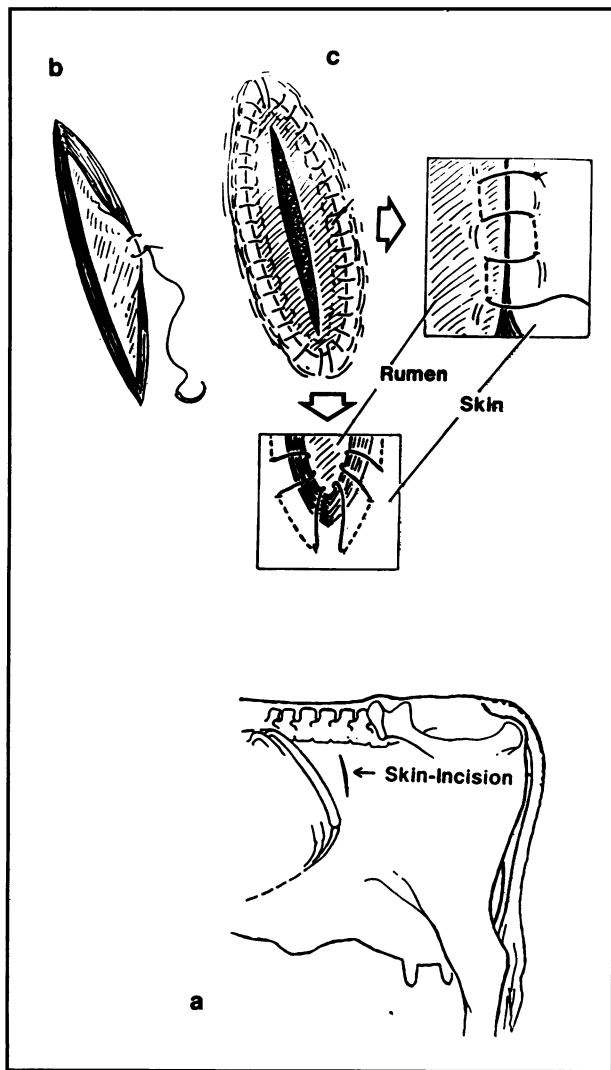


Figure 1. Rumenotomy by rumen skin suturing fixation. a) Skin incision. b) First suture bite through the rumen and skin. c) Completed suture, rumen is incised. Right square: Enlarged schematic of the suture pattern. Lower square: Suture pattern at dorsal and ventral commissures for better peritoneal seal.

operation. They were restrained in a conventional stock. The left flank was clipped, washed, and disinfected. Local anesthesia was carried out with a paravertebral nerve block. Nerves thoracic (T) 13, lumbar (L) 1, 2, and 3 were blocked. The skin was aseptically prepared by use of povidone iodine, and the animal was draped. Sterile gowns and gloves were used.

Rumen skin suturing fixation (RSSF)

Following laparotomy, the rumen was pulled slightly toward the incision. The rumen was sutured to the skin using No. 2 silk and a continuous Connell suture pattern. The suture pattern started midway down the caudal side of the incision, continued ventrad to the ventral commissure of the incision, dorsad on the cranial side of the incision to the dorsal commissure, and then ventrad again to the starting point (Figure 1). The suture was pulled tight to invert the skin edges under the rumen for a good seal. The rumen was incised and explored as described in the literature (2). The ruminal edges were then washed and the 1st layer of the rumen was closed

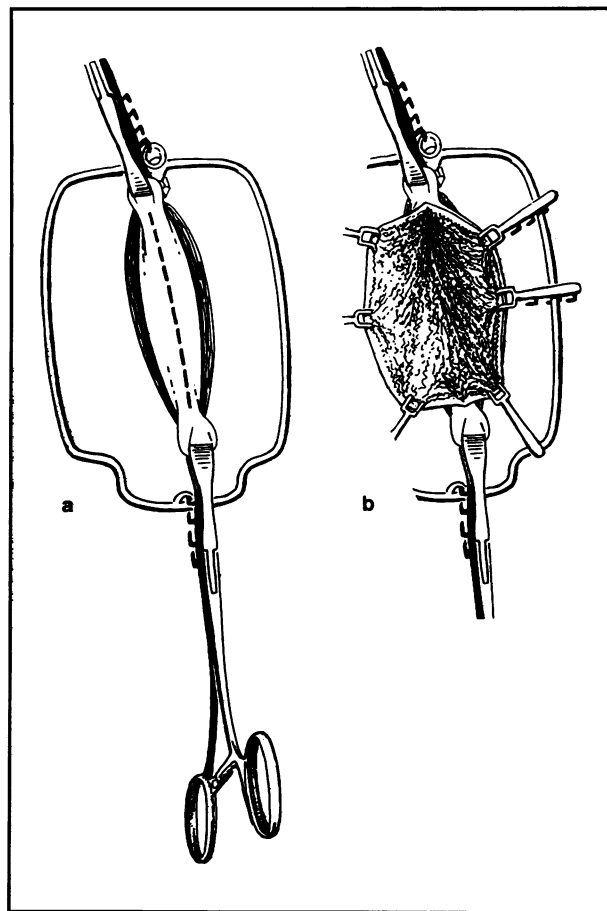


Figure 2. Weingarth's ring rumenotomy. a) Application of Weingarth's ring, the rumen is anchored to the ring dorsally and ventrally. b) Rumen is incised and fixed to either side of the ring by hooks.

in a Lembert pattern, using No. 2 chromic catgut. The incision site was rinsed with sterile saline, and the surgeons rescrubbed and regloved. The rumen to skin suture was removed and a 2nd layer of rumen closure was placed using a Cushing pattern with the same type of suture material, and inverting the holes made by the rumen to skin suture. Following a final rinse of the rumen with sterile saline, the laparotomy incision was closed routinely. The transverse abdominis muscle and peritoneum were sutured together in a simple continuous pattern, using No. 2 chromic catgut. Before tying the last suture, air was forced out of the abdomen by someone pushing into the opposite flank. The remaining muscle layers and subcutaneous fascia were sutured separately, but in the same manner as the 1st layer. The skin was sutured using a lockstitch pattern with No. 2 silk.

Weingarth's ring rumenotomy (WRR)

Following laparotomy, a Weingarth's frame was fixed to the dorsal commissure of the incision by its thumb screw. The rumen was fixed to the ring as described in the literature (4). As the rumen wall was incised, hooks were placed into the cut edge of the rumen wall, pulled out, and hooked around the frame until the rumen had been reflected outward all the way around the incision (Figure 2). The ruminal cavity was explored as in the RSSF technique, using a rumen shroud. The closure

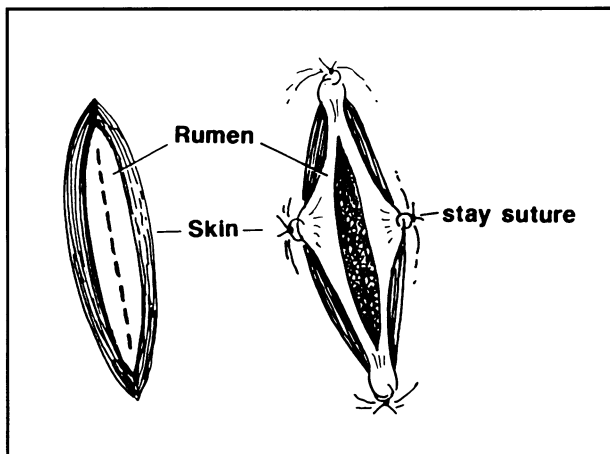


Figure 3. Stay suture rumenotomy. The rumen is sutured to the skin ventrally, dorsally, cranially, and caudally prior to being incised.

was similar to that for RSSF, including inversion of the traumatized area of the rumen made by the forceps. Abdominal wall closure was routine.

Stay suture rumenotomy (SSR)

Following laparotomy, the rumen was gently pulled out of the incision, and the rumen wall was anchored to the incision dorsally, ventrally, cranially, and caudally by 4 sutures into the skin and rumen wall, using No. 2 nylon suture (Figure 3). The rumen was then opened and the edges were grasped with artery forceps. Exploration of the ruminal cavity was carried out using a rumen shroud. Ruminal and abdominal closure were as described for RSSF.

Rumen skin clamp fixation (RSCF)

Six to 8 Backhaus towel clamps were used for this technique. Following laparotomy, the rumen was gently pulled out of the incision and firmly anchored to the skin dorsally and ventrally by towel clamps. The rumen was opened and its edges were fixed cranially and caudally to the skin incision using towel clamps. Additional clamps were used to secure the rumen edges to the skin between previously placed clamps (Figure 4). The clamp handles were pointed away from the incision and the rumen edges overlapped the skin edges by 2 to 3 cm. Removal of ingesta and exploration of the rumen was done as before. The rumen was rinsed with sterile saline. For closure, the clamps on the cranial and caudal side were removed first and the dorsal and ventral clamps were left on. The 1st layer was closed as in the other procedures, while closure of the 2nd layer was carried out after removal of the dorsal and ventral clamps, allowing for inversion of traumatized areas of the rumen.

All the operations were performed by the same surgical team. No antibiotics were used either preoperatively or postoperatively. Physical examinations were carried out daily, including evaluation of heart rate, respiratory rate, rectal body temperature, and general status. Blood samples were collected from the jugular vein daily, for 4 consecutive days after surgery, for determination of

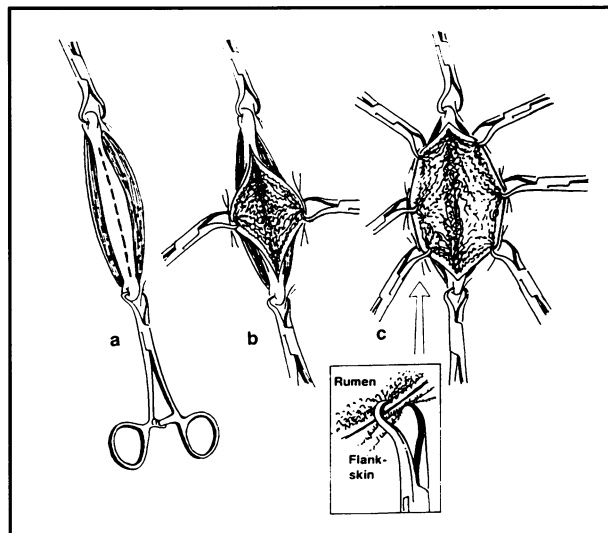


Figure 4. Rumenotomy by rumen skin clamp fixation. a) The rumen is fixed to the skin dorsally and ventrally by 2 towel clamps. b) The rumen is incised and fixed to skin on either side. c) The ruminal incision is extended and fixed to the skin by more clamps. Lower square: Towel clamps properly applied to overlap rumen wall over the skin.

total and differential leukocyte counts. The animals were slaughtered 2 mo following the operation.

The statistical calculations were made using one-way analysis of variance followed by the Duncan procedure by means of a calculation program (SPSS/PC V 2.0, SPSS Inc. Chicago, Illinois, USA). A significance level ($P < 0.05$) was assumed.

Results

Rumenotomy by the RSSF procedure took significantly ($P < 0.003$) longer than by the other 3 techniques. It ranged from 21 to 25 min (mean 22.5, $s = 2.3$ min), due to the time spent suturing the rumen to the skin and subsequently removing these sutures for ruminal closure. The mean surgical times (skin incision to skin closure) for the RSSF, WRR, SSR, and RSCF techniques were 76.00, $s = 2.9$, 55.7, $s = 5.4$, 51.2, $s = 5.3$, and 55.5, $s = 5.6$ min, respectively. The mean body temperature of each group was compared with its presurgical mean value (Table 1). Significant differences were observed only in the group treated by the SSR technique ($P < 0.05$), where the postoperative body temperature levels during the first 4 d were significantly higher than the preoperative levels. The total WBC counts were reduced during the 1st postoperative day and increased again on the 2nd postoperative day in all groups ($P > 0.05$). Only after the SSR procedure did the total WBC count increase significantly ($P < 0.05$) on the 4th postoperative day. The neutrophil/lymphocyte (N/L) ratio also increased significantly ($P < 0.05$) in this group on the 4th postoperative day. The animals appeared anorectic, emaciated, with a rough hair coat, and had poor carcasses at slaughter.

At slaughter, all the ruminal and abdominal incisions had healed grossly with no complications. There were negligible local adhesions at the rumenotomy site in 1 animal in the RSSF group, a few small local fibrous bands in 1 animal in the RSCF group, and local fibrous

Table 1. Mean body temperatures, total leukocyte counts, and neutrophil to lymphocyte ratios (N/L) in 4 groups of 5 cattle treated by rumenotomy

Surgical group	Mean body temp. (°C)	Mean total WBC ($\times 10^9/L$)	Mean N/L ratio
preoperative	38.3, <i>s</i> = 0.44	8.8, <i>s</i> = 1.8	0.44, <i>s</i> = 0.05
RSSF postoperative			
day 1	38.7, <i>s</i> = 0.42	7.7, <i>s</i> = 1.5	0.42, <i>s</i> = 0.06
day 2	38.8, <i>s</i> = 0.39	7.4, <i>s</i> = 1.7	0.40, <i>s</i> = 0.08
day 3	39.0, <i>s</i> = 0.62	9.4, <i>s</i> = 1.6	0.50, <i>s</i> = 0.08
day 4	39.0, <i>s</i> = 0.56	9.8, <i>s</i> = 9.4	0.52, <i>s</i> = 0.07
preoperative	38.2, <i>s</i> = 0.59	10.0, <i>s</i> = 8.0	0.50, <i>s</i> = 0.10
WRR postoperative			
day 1	39.3, <i>s</i> = 0.64	8.5, <i>s</i> = 7.4	0.49, <i>s</i> = 0.10
day 2	39.4, <i>s</i> = 0.62	8.0, <i>s</i> = 1.0	0.45, <i>s</i> = 0.10
day 3	39.4, <i>s</i> = 0.60	11.5, <i>s</i> = 1.1	0.64, <i>s</i> = 0.12
day 4	39.4, <i>s</i> = 0.55	12.5, <i>s</i> = 1.8	0.68, <i>s</i> = 0.10
preoperative	37.8, <i>s</i> = 0.24	9.0, <i>s</i> = 1.6	0.56, <i>s</i> = 0.13
SSR postoperative			
day 1	39.2, <i>s</i> = 0.46 ^a	6.5, <i>s</i> = 1.2	0.51, <i>s</i> = 0.10
day 2	39.2, <i>s</i> = 0.70 ^a	5.9, <i>s</i> = 1.5	0.45, <i>s</i> = 0.10
day 3	39.2, <i>s</i> = 0.42 ^a	11.6, <i>s</i> = 1.9	0.73, <i>s</i> = 0.08
day 4	39.3, <i>s</i> = 0.56 ^a	12.6, <i>s</i> = 1.5 ^a	0.79, <i>s</i> = 0.09 ^a
preoperative	38.3, <i>s</i> = 0.48	9.4, <i>s</i> = 1.7	0.46, <i>s</i> = 0.09
RSCF postoperative			
day 1	39.0, <i>s</i> = 0.65	8.1, <i>s</i> = 2.0	0.42, <i>s</i> = 0.06
day 2	39.0, <i>s</i> = 0.63	7.8, <i>s</i> = 1.2	0.39, <i>s</i> = 0.07
day 3	39.2, <i>s</i> = 0.70	10.3, <i>s</i> = 1.6	0.56, <i>s</i> = 0.13
day 4	39.2, <i>s</i> = 0.56	10.7, <i>s</i> = 1.3	0.58, <i>s</i> = 0.13

WBC — white blood cell
 RSSF — rumen skin suturing fixation
 WRR — Weingarh ring rumenotomy
 SSR — stay suture rumenotomy
 RSCF — rumen skin clamp fixation
^adata are significantly different ($P < 0.05$)

adhesions in 2 animals in the WRR group. There were, however, extensive fibrous adhesions present in 3 animals in the SSR group, including a few small abscesses in 1 animal and a large peritoneal abscess in another. The abscess (36 × 14 × 23 cm) was found between the rumen and left abdominal body wall. Advantages and disadvantages of the 4 rumenotomy techniques are summarized in Table 2.

Discussion

The results in Table 1 demonstrate that rumenotomy by the RSSF technique was superior to rumenotomy by the WRR and SSR techniques, because there were no significant changes in body temperature or total WBC count, and there were only a negligible number of adhesions. The RSCF and RSSF techniques were equivalent, since although the postoperative findings in the RSCF group were slightly higher than those in the RSSF group, the RSCF technique required a shorter surgical time. The changes in body temperature, total WBC count, and neutrophil to lymphocyte (N/L) ratios in the WRR group, although not significant, were greater than in the RSSF or RSCF groups. With removal of rumen ingesta and reduction in the intraruminal pressure, the hooks in WRR technique tended to become loose, providing room for spillages and contamination of the

peritoneal cavity. Reduction in the number of lymphocytes, as indicated by the increased N/L ratios (Table 1), and increases in the total WBC counts, along with presence of eosinophils, suggested that mild inflammation occurred with the SSR group (5).

Antibiotics were not used in animals in this study, because avoiding the use of antibiotics for an operation has economic advantages, especially in food animals. In the case of emergency slaughter, antibiotic residues in edible tissues and the subsequent public health hazard are avoided. Therefore, choosing the correct technique and doing it as aseptically as possible could have considerable economic value.

Rumenotomy by RSSF, as performed in this study, was slightly different from that previously reported (2). Special attention was focused on the dorsal and ventral incision commissures, so that there was a good overlap of rumen on the skin where the leakage of ingesta into the peritoneum was most likely to occur (Figure 1). Although No. 2 silk was used for RSSF in this study, almost any nonabsorbable suture material could have been used.

Other techniques or devices for rumenotomies in cattle have been described, such as, the rumenotomy board (4) and the Danish rumenotomy set (2), which are more or less similar to Weingarh's ring. Rumenotomy by the Gotze method requires that the rumen be sutured to the peritoneal membrane by a continuous suture

Table 2. Comparison of 4 rumenotomy techniques

Technique	Advantage	Disadvantage
RSSF	<ul style="list-style-type: none"> — Clean wound after rumen closure — Fewer postoperative complications than SSR and WRR technique — Good for all purpose rumenotomy, especially for rumen lavage — No special instruments needed — No assistant required 	<ul style="list-style-type: none"> — Time consuming — Failure to invert suture holes made in the rumen will sometimes cause leakage and peritonitis
WRR	<ul style="list-style-type: none"> — Fast technique — Good for foreign body removal, impactions, and grain overloads 	<ul style="list-style-type: none"> — Easily displaced — Not a clean wound after rumen closure — Need special instrument — Requires assistant — Not good for frothy bloats or rumen lavage
SSR	<ul style="list-style-type: none"> — No special instruments needed — Good for fast removal of foreign body 	<ul style="list-style-type: none"> — Contamination of surgical wound and peritoneum — Possible peritonitis and abscessation — Requires assistant
RSCF	<ul style="list-style-type: none"> — Clean wound after rumen closure — Fast technique — No special instruments needed except rumen shroud — No assistant required — Fewer postoperative complications than with SSR and WRR techniques — Good for all purpose rumenotomy 	<ul style="list-style-type: none"> — If rumen shroud is not used, clamps may interfere with operator's hand

RSSF — rumen skin suturing fixation
WRR — Weingarh ring rumenotomy
SSR — stay suture rumenotomy
RSCF — rumen skin clamp fixation

pattern before entering the rumen (7); it has the disadvantage that the peritoneum has less holding power than the skin and contamination of the abdominal muscle layers is almost inevitable.

A single layer of continuous inverting closure is adequate for the rumen (2,4), except when it is largely distended (2) or if there is any question of the viability of the rumen wall. In this study, the rumen was closed by 2 inverting suture patterns. The 1st layer closure limited the source of contamination and allowed cleaning of the rumen and wound, while the 2nd layer was supportive and allowed for inversion of all traumatized areas close to the incision that were not previously visible. Haven *et al* (6) also preferred double layer ruminal closures.

Rumenotomy by RSSF is the best procedure, but it requires the longest time. Rumenotomy by the WRR procedure is usable, but requires attention during the operation to prevent loosening of the hooks and spillage of ingesta into the peritoneal cavity. Rumenotomy by RSCF has similar advantages to the RSSF procedure, but it requires a shorter operative time, so it can be considered as a safe alternative technique for rumenotomy.

Acknowledgment

The authors thank Mattias Haab of the Veterinary Surgery Clinic of the University of Zurich for preparing the illustrations. CVJ

References

1. Amstutz HE. Bovine Medicine and Surgery. 2nd ed. Vol 2. California: American Veterinary Publications Inc, 1980: 1202-1210.
2. Turner AS, McIlwraith CW. Technique in Large Animal Surgery. 2nd ed. Philadelphia: Lea & Febiger, 1989: 268-273.
3. Hessamizadeh C. Radiological and surgical study of foreign body ingestion in cattle (DVM Thesis). Shiraz, Iran: Shiraz University, 1987.
4. Hofmeyr CFB. The digestive system. In: Oehme FW, ed. Textbook of Large Animal Surgery. 2nd ed. Baltimore: Williams & Wilkins, 1988: 448.
5. Schalm OW, Jain NC, Carrol EJ. Veterinary Hematology. 3rd ed. Philadelphia: Lea & Febiger, 1975: 141-143, 522.
6. Haven ML, Wichtel JJ, Bristol DG, Fetrow JF, Spears JW. Effects of antibiotic prophylaxis on postoperative complications after rumenotomy in cattle. J Am Vet Med Assoc 1992; 200: 1332-1335.
7. Rosenberger G. Krankheiten des Rindes, Berlin: Paul Parey, 1970: 226-227.
8. Jubb KVF, Kennedy PC, Palmer N. Pathology of Domestic Animals. 3rd ed. Vol 2. New York: Academic Pr, 1985.