

# How to Insert and Manage a Subpalpebral Lavage System

Ann E. Dwyer, DVM

Author's address: Genesee Valley Equine Clinic PLLC, 925 Chili Scottsville Road, Scottsville, NY 14546; e-mail: [adwyer@rochester.rr.com](mailto:adwyer@rochester.rr.com). © 2013 AAEP.

## 1. Introduction

A subpalpebral lavage system (SPL) is an ophthalmic catheter that delivers topical liquid medication onto the surface of the equine cornea. The system consists of a long silicone tube that passes through the upper or lower eyelid and is secured to the facial skin. The tubing, which is woven through the mane and draped along the crest of the neck, ends in a closed port that is secured to the mane. Medication is injected into the port and pushed through the tube by an air bolus or by additional medications to reach the tear film.

An SPL is an essential tool for treating serious equine ocular conditions such as corneal lacerations, deep ulcers that are infected or melting, or severe uveitis.<sup>1</sup> Management of these ocular problems requires multiple treatments per day and may extend for several weeks. SPL medication is delivered without the handler touching the face or periocular region; therefore, treatment of fractious or painful eyes is simplified. An SPL makes therapy as easy as possible for the caretakers and ensures that all medication reaches the tear film to medicate the cornea. The use of an SPL is mandatory in any globe that is at risk for rupture caused by tectonic instability of the cornea or sclera.

The use of an SPL is not limited to the hospital setting. Practitioners can place SPLs and train farm personnel to implement treatment in the field. SPLs can be used on any size of horse and have been used to treat neonates and foals as well as adults. The use of an SPL increases the safety and efficacy of topical therapy, improves compliance, and reduces caretaker fatigue in complex, multidrug treatment plans.

## 2. Materials and Methods

Commercial SPL kits are available through two veterinary manufacturers.<sup>a</sup> This author prefers kits that provide a solid 12-gauge insertion trochar that is swaged onto the silicone tubing.<sup>b</sup> The kits offer a choice of a straight or angled insertion trochar; practitioners who use a gloved finger as a guide to slip the trochar beneath the lid may favor the angled version. The kits are sold in 36- and 60-inch lengths with a single 5F lumen diameter. The 60-inch kit is most versatile because the longer tubes are suitable for large horses and can be shortened to accommodate small patients. The 36-inch tubes may be too short for use in some horses.

The following checklist summarizes all items the author commonly uses to facilitate restraint, seda-

---

## NOTES

tion, and site preparation and to secure the tube and construct a durable injection port:

- SPL Kit, 60 inches
- Sterile gloves (for trochar insertion)
- Topical bottle of 2% povidone iodine solution and gauze 4 × 4 gauze pads (to clean the periocular region)
- Proparacaine or tetracaine topical ophthalmic solution (to numb the corneal surface)
- Mepivacaine or lidocaine injectable (for blocking the eyelid)
- Several 3-mL syringes
- Detomidine (for sedation)
- Small rubber bands (to braid the mane)
- A roll of duct tape (to make butterfly tabs for securing the tubing)
- A roll of white adhesive tape (to make mane braids snug and create the base for the injection port)
- 20-gauge, 1.25-inch catheter (to create injection port)
- Male catheter cap (to create the injection port)
- Wooden tongue depressor
- Nonabsorbable suture (1–0 to 1 diameter, to secure the tube to the skin)
- Olsen-Hegar needle holders, 6 inches long (for tube suturing)

SPL treatment plans require a large quantity of tuberculin (1-mL) syringes and 25-gauge, five-eighths–needles. These may be dispensed in box quantities. A selection of colored tape rolls will aid in labeling different medication syringes.

#### Installation

The clinician should ensure that the horse is restrained in a clean, wind-free, well-lit, quiet area. Placement of an SPL is not difficult, but it carries a risk to the patient because insertion involves brief passage of a sharp trochar over the corneal surface. The clinician must insist that barn activity be kept to a minimum when the trochar insertion takes place. All necessary items should be placed on a clean, elevated surface. Folding tables sold for dog grooming make handy equipment stages in the field.<sup>c</sup>

The owner or veterinary assistant should braid the mane and forelock into a series of “pigtails” that will serve as guides to secure the tubing to the crest of the neck. Because the tubing may be maintained for several weeks, it is helpful to secure the top and bottom of each pigtail with a wrap of adhesive tape so the braids do not loosen.

Insertion is safest when the horse’s mandible is supported on a solid object (stacked bales, oil drum, recycling bin, etc). Stocks are helpful if they are available. The horse should be sedated heavily with the use of detomidine at a dose of 0.02 to 0.04 mg/kg. Deep sedation will cause the horse to rest the mandible on the support material, and the



Fig. 1. A wheeled recycling bin or other stationary prop is used to support the horse’s mandible for safe SPL insertion.

handler will only have to lightly brace the head while standing on the opposite side to the affected eye (Fig. 1).

The periorbital region is cleaned with a 1:50 povidone iodine/saline solution. The target area for trochar insertion is blocked with local infiltration of mepivacaine or lidocaine. If the tube is intended for the upper eyelid, an auriculopalpebral and supra-orbital block should be performed. One milliliter of topical anesthetic is drawn up into a tuberculin or 3-mL syringe and sprayed onto the corneal surface with the use of the hub of a broken-off 25-gauge needle as a spraying device.

The SPL tube can be inserted into either the upper eyelid or the lower eyelid (Fig. 2A,B). Some clinicians think that the use of the dorsotemporal fornix of the upper lid provides beneficial “waterfall effect” in which the medication cascades over the ocular surface. Others argue that insertion through the ventronasal cul-de-sac of the lower lid provides protection against iatrogenic ulceration because the nictitans is a barrier if the tube footplate migrates in from the conjunctiva. There is good evidence to support that a lower-lid SPL is an effective and safe choice.<sup>2</sup> Ultimately, the choice will depend on clinician preference, patient temperament, and location of the lesion. Securing the tube to the face can be done in a linear pattern from upper eyelid insertion sites. If the lower lid is used, the tube must be secured to the face in a J-shaped pattern.

The following steps (Fig. 3A–D) describe the insertion process once the mane is braided, the horse

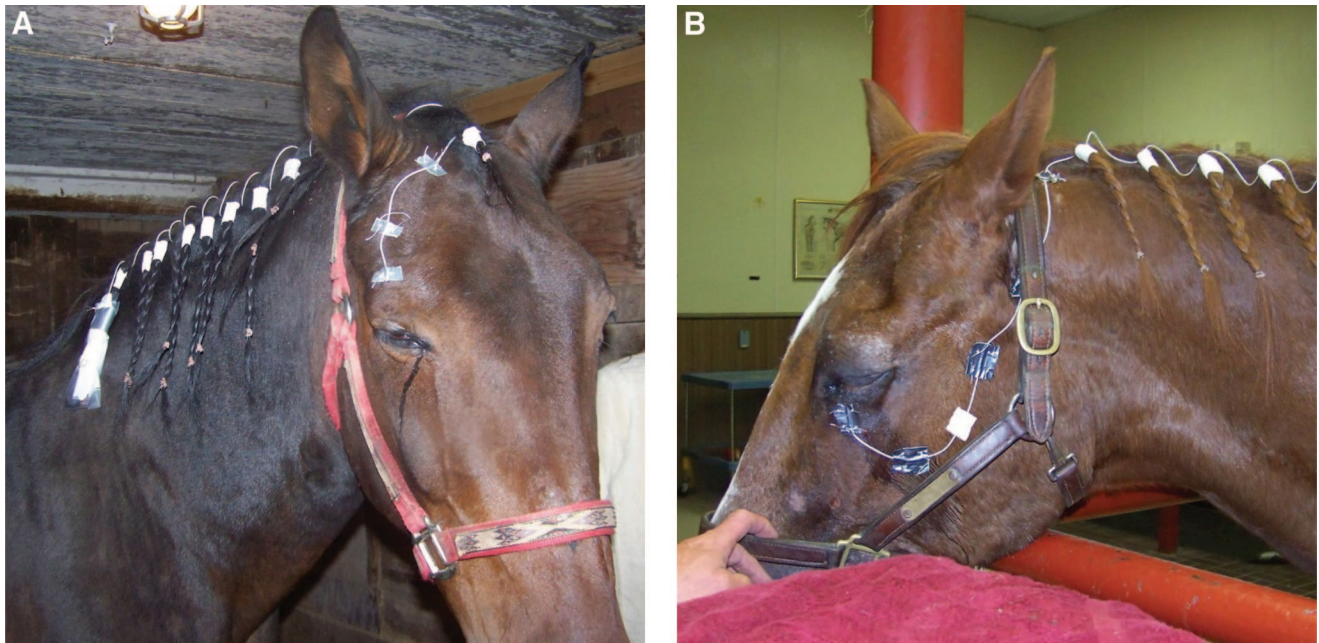


Fig. 2. A, SPLs can be inserted into the upper or lower lid. This system was inserted into the upper eyelid. B, This SPL was inserted into the lower eyelid.

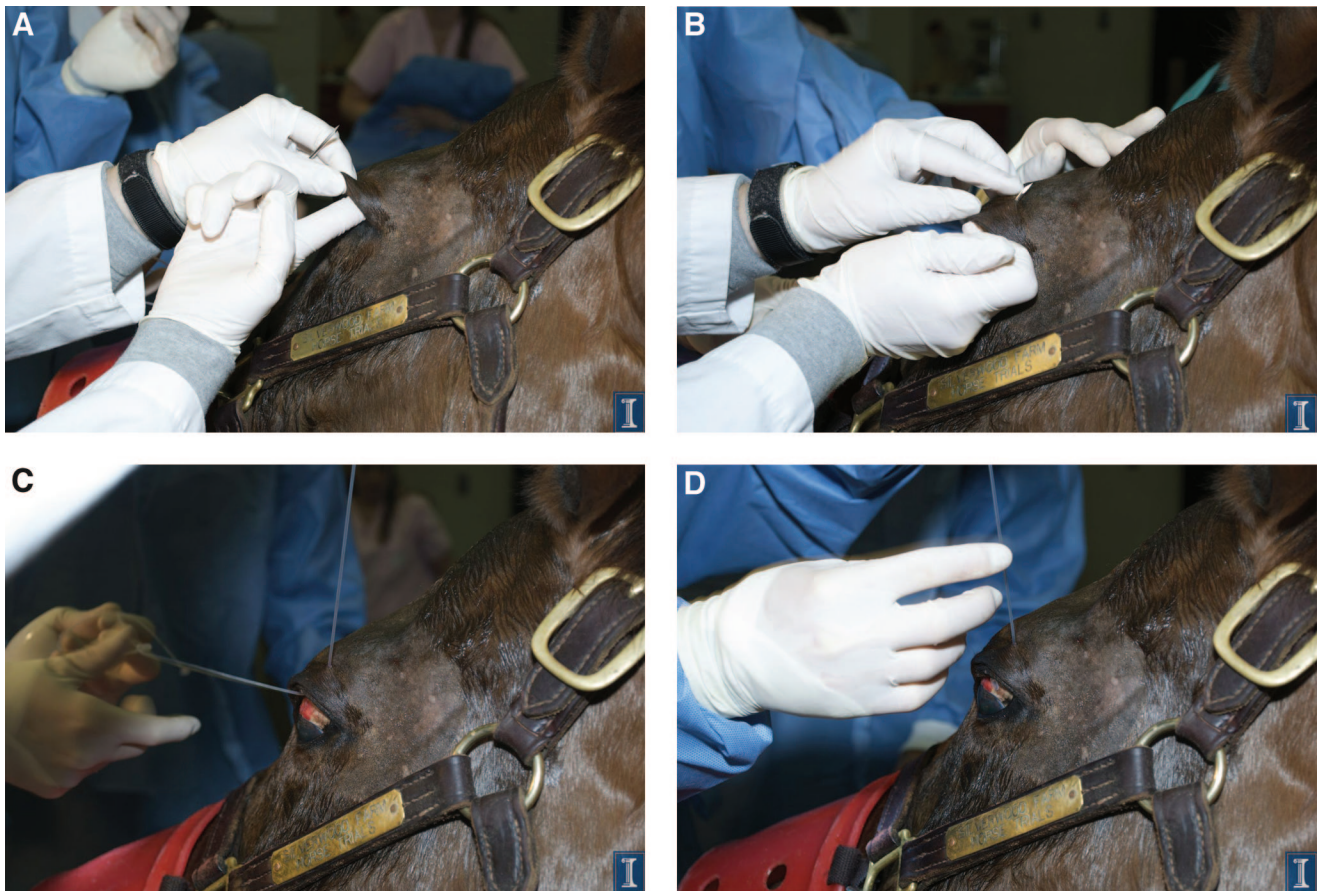


Fig. 3. A, SPL insertion: A gloved finger is used to probe the depths of the fornix and test the horse's reaction. B, The trochar is carefully pushed through the palpebral conjunctiva and eyelid. C, The SPL tubing is pulled through the eyelid. D, The tubing footplate is pulled under the lid. Care must be taken to align the angle of the footplate with the angle of the palpebral conjunctiva. Photo courtesy of University of Illinois Comparative Ophthalmology Service, Amber Labelle, DVM, DACVO.

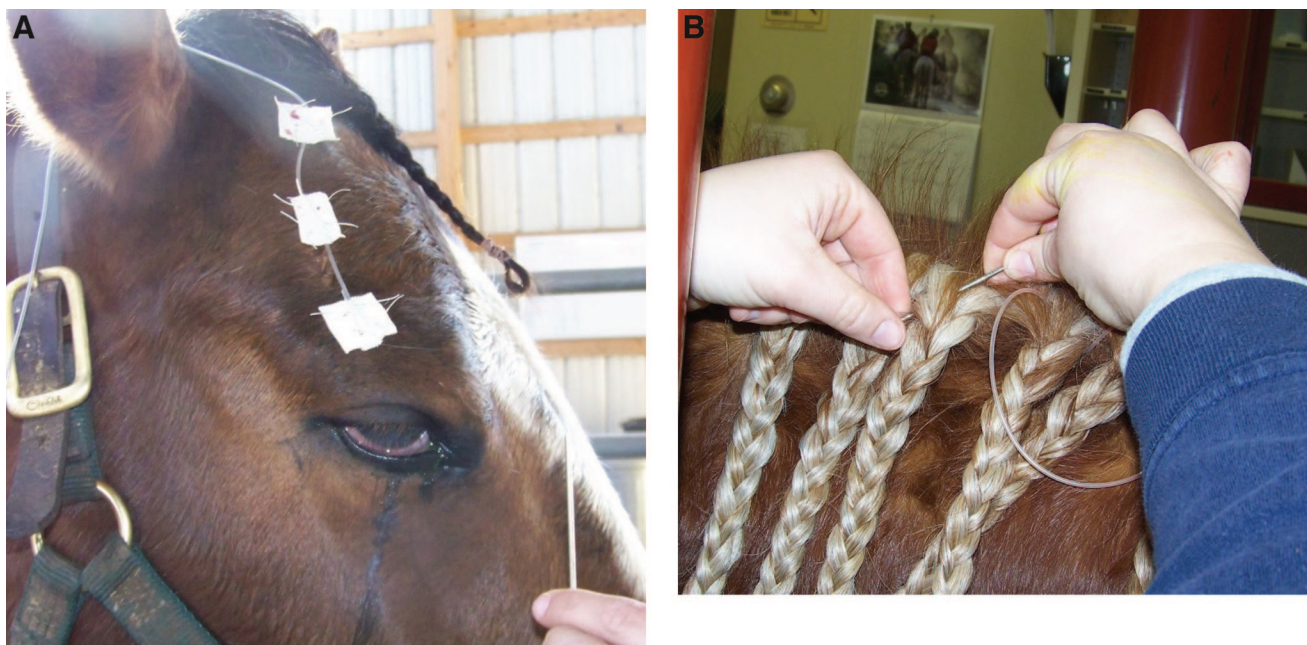

Fig. 4. A, Adhesive or duct tape wings are folded over the tubing and sutured to the facial skin. B, The SPL trochar is used to weave the tubing through the mane.

is sedated and blocked, and topical anesthetic is applied to the cornea:

- (1) A gloved finger or a blunt sterile probe (cotton-tipped wooden swab or the hollow insertion tube provided with the SPL kit) into the deepest palpebral reflection is used to test the eyelid block and tolerance of instruments at the site. Additional sedation and/or anesthetic is indicated if the horse reacts (Fig. 3A).
  - (2) With the use of either a gloved finger or the hollow insertion tube as a guide, the trochar point is then carefully advanced to the target puncture site adjacent to the orbital rim. The trochar tip is pushed through the lid skin (Fig. 3B). The trochar and tube are then pulled through the eyelid until the disc-shaped footplate of the SPL tube rests against the palpebral conjunctiva. Care is taken to ensure that the oblique angle of the footplate matches the slant of the eyelid conjunctiva and that the footplate is snug against the mucosa (Fig. 3C,D).
  - (3) The section of the tubing that exits the eyelid and traverses to the forelock is sutured to the facial skin (Fig. 4A). The author makes two to four half-inch wide “butterfly” wings out of duct tape or adhesive tape and fastens the first wing to the tubing at the eyelid skin exit hole. Other wings are taped to the tubing at appropriate intervals toward the ear. The wings are then sutured to the skin with the use of four simple interrupted sutures per wing. Alternatively, the tubing can be laced through the plastic U-shaped guides provided with the SPL kit, and the guides can be sutured to the skin in a similar pattern.
  - (4) The trochar is used to pull the tubing through the base of the forelock braid and then weave the tubing through the mane braids, with the use of a consistent “under-over” or “over-under” pattern of inserting the trochar into the center of the braid base (Fig. 4B). A stout braid near the withers is selected as the anchor for the injection port. When this braid is reached, the trochar is capped for safety before assembly of the port.
  - (5) The tubing is cut near the withers. The unused portion may be saved for future repairs.
  - (6) A 1.25-inch, 20-gauge catheter is carefully threaded into the lumen of the open tubing with the use of the catheter stylet (with the sharp tip pulled back slightly into the catheter lumen) as a probe to aid in the sleeving process (Fig. 5A). The stylet is removed, and a standard male catheter cap is twisted onto the catheter hub.
  - (7) The injection port is secured to the mane braid as described below.
- The author prefers to cut a wooden tongue depressor in half and use two folded 4 × 4 gauze squares as a “bed” for the capped injection port, leaving a half inch of tongue depressor extending beyond the place where the cap rests (Fig. 5B). Adhesive tape is wound around the tubing, catheter, and gauze to seat the catheter firmly, leaving only the injection

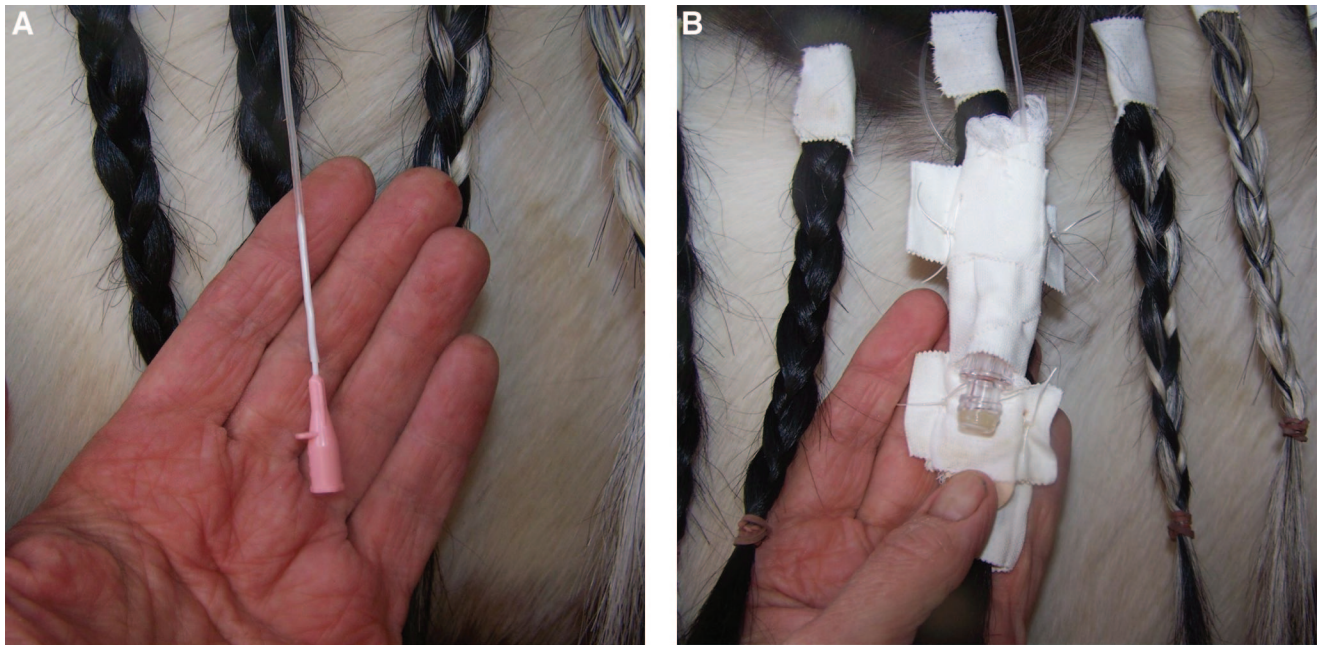


Fig. 5. A, The 20-gauge, 1.25-inch catheter is inserted into the SPL tubing near the withers to create the injection port. B, The injection port is closed with a male catheter cap. The tubing end and port are braced with a few pieces of gauze and a tongue depressor and taped and sutured to the anchoring mane braid.

port exposed. Tape wings are then used to secure the “braced” injection port to the anchoring braid. In some cases, tape wings are then sutured to the braid twists to further ensure that the port is well attached to the mane braid. Care taken with securing the port should ensure that the braid will not unravel with normal stable activity, even if the device remains in place for several weeks. A heavy plastic bag can be taped over the injection assembly to keep it clean.

Neonates and very young foals must undergo short-term general anesthesia or heavy sedation to induce lateral recumbency for safe insertion of an SPL, but all other steps in the process remain the same. Very young foals will not have enough mane to make braids, but adhesive tape can be wrapped around short mane hairs to create a series of tufts that will serve the same purpose. The injection port assembly may need to be sewn to the skin (Fig. 6). Some clinicians slip a section of wide stockinette over the head and neck of the foal to protect the tubing from damage. Holes can be cut in the stockinette to provide openings for the eyes.

A series of tape butterfly guides must be sutured close to the crest of the neck to secure an SPL in an adult horse that has had the mane shaved off (roached).

#### Use of an SPL to Deliver Ocular Medication

Treatment involves injection of medication into the tubing cap. The tongue depressor support taped to the mane braid makes a secure handle to access the injection cap. Medication that has been drawn up

into a tuberculin syringe is injected through a 25-gauge, five-eighths-inch needle (Fig. 7). Most medication is dosed at a volume of 0.2 mL. Some very costly medications are dosed at a volume of 0.1 mL.<sup>d</sup> The medication is then “pushed” toward the eye by a

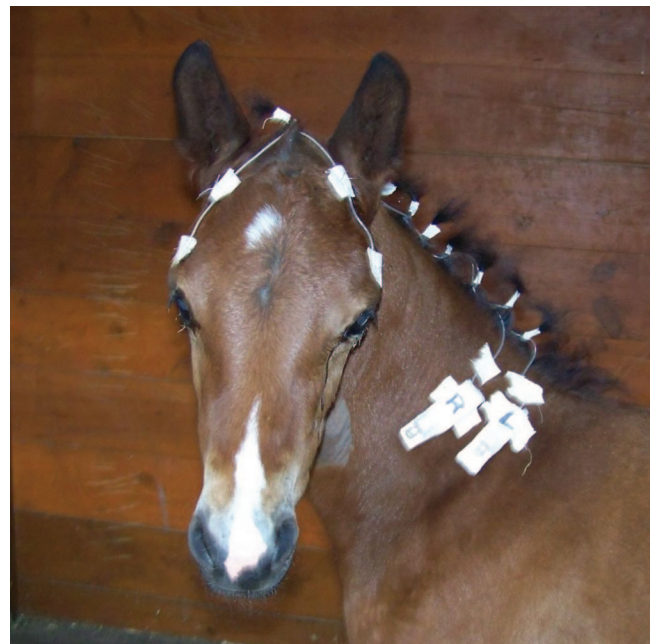

Fig. 6. Tufts of mane can be used as a channel for SPL tubing in young foals. Two injection ports were secured to the skin of this foal's neck.

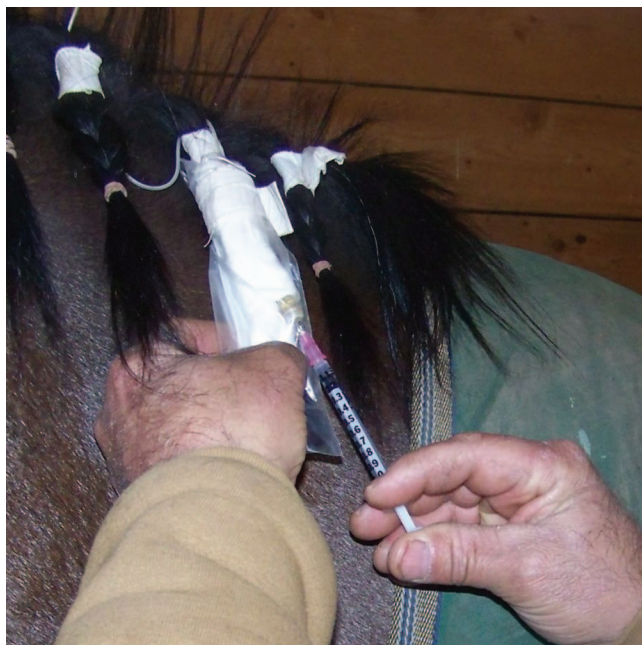


Fig. 7. Medication is injected into the SPL through a 25-gauge, five-eighths-inch needle attached to a tuberculin syringe. The injection port has been covered with a plastic bag.

second injection of air. The air injection should be done slowly to minimize discomfort and reduce washout. A volume of 1.5 to 2.0 mL of air is sufficient to push the medication beyond the footplate, where it then mixes with the tear film. Most horses will react with a slight head shake when the medication exits the tube.

Almost all SPL medication schedules require that multiple drugs, which may include mydriatics, antibiotics, anti-fungals, anti-inflammatories and anti-collagenases, are given several times a day. Most clinicians advise that each drug be given separately, with an interval of a few minutes before the next product is injected. Definitive research has not been performed to determine if “stacking” medication in a tube (injecting several products one after another and then using the air bolus to propel all of them at once to the eye) is as effective as individual injections, but a large volume (>0.4 mL) of liquid that reaches the eye all at once may spill out onto the face. Alternately, the SPL line can be loaded with medication, and each individual dose then may be administered at 5-minute intervals so that only 0.2 mL of medication is administered to the ocular surface with each dose.

Battery-powered, single-use infusion pumps designed to deliver continuous ocular medications into an SPL are commercially available.<sup>e</sup> These pumps have a 10-mL fluid reservoir that can be filled with liquid topical medication. They can be ordered in flow rates that vary from 0.06 mL per hour (10-mL reservoir is slowly discharged over 7 days) to 1.0 mL per hour (the entire reservoir is discharged in 10 hours). “T” and “W” adaptors that allow more than

one pump to be hooked to the same SPL are available from the manufacturer. It is important to follow the directions when filling the reservoir and securing the discs to the SPL port because the pumping assembly relies on the intake of a small volume of air into the device to deflate the reservoir. Care must be taken to ensure that the air intake valve is not obstructed. The disc bladder should be checked periodically to ensure that the medication reservoir bag is deflating on schedule. When the disc is empty, it can be disconnected from the SPL and replaced with a new disc.

The author has used these pumps a few times in fractious horses and in situations in which manual treatment was not practical. Some clinicians have reported good success with these devices. It is important to consider the effect of ambient temperature on drug stability when using such devices because some drugs may not remain stable with prolonged exposure to room temperature.

#### Maintenance

The SPL catheter cap should be cleaned daily with application of an alcohol wipe. Catheter caps are changed at 3- to 7-day intervals in hospitalized patients. Cases handled in the field may undergo cap changes at veterinary recheck appointments. Some clinicians advise running a small amount (1 mL) of 1:50 povidone iodine/saline solution through the tube several times a week as an antiseptic, then flushing the tube lumen with air before the next scheduled medication application. Experimental evidence suggests that colonization of the SPL system by bacteria is uncommon; thus, the need

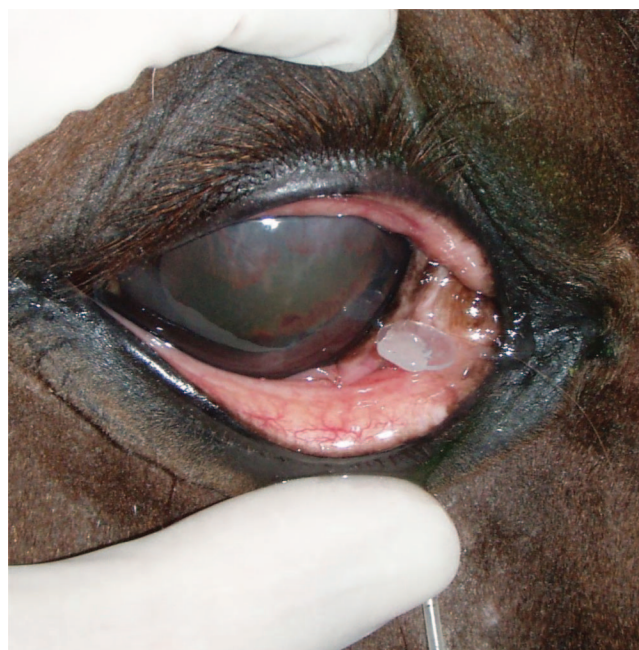

Fig. 8. The SPL footplate is removed by use of the adjacent section of tubing as a “pole” to push the disc away from the conjunctiva.

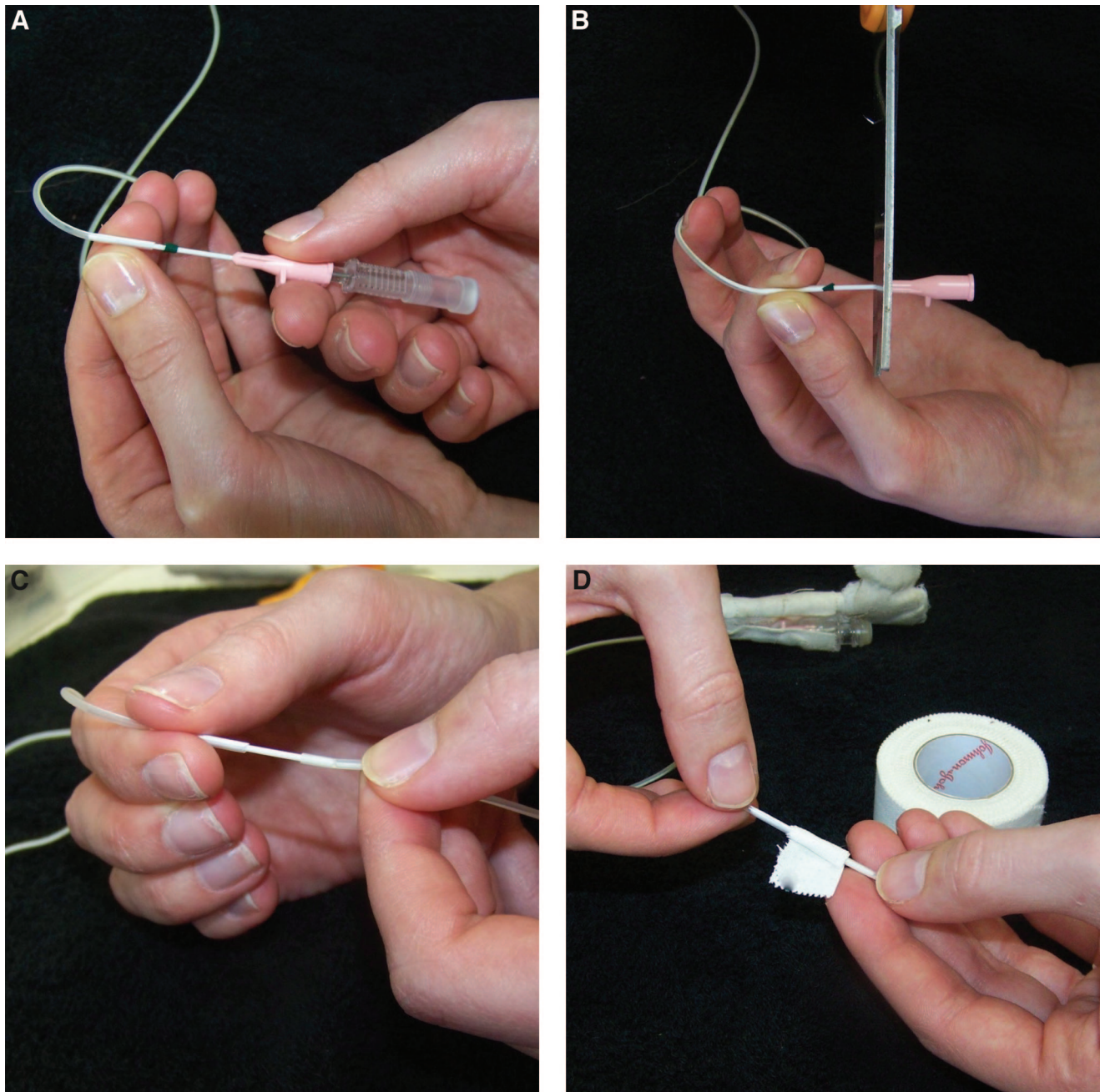


Fig. 9. A, SPL repair: The 20-gauge, 1.25-inch catheter is threaded halfway into one end of the broken tubing. The catheter stylet is then removed. B, The hub of the catheter is cut off. C, The other end of the broken SPL tubing is carefully “shimmied” onto the remaining length of catheter until the two ends meet. D, The spliced tubing section is wrapped with tape, then sutured with a separate tape wing to the horse’s skin.

for lavage with an antiseptic solution is unconfirmed.<sup>3</sup> The tube suspension arrangement (braids, sutured tape wings) may require rebraiding, resuturing, or new tape application.

#### Removal

SPL tubes are easily removed in the standing, sedated horse by cutting the tubing a few centimeters away from the fornix or cul-de-sac exit site and

removing all wings or guides that attach the cut section to the face. The tubing that remains attached to the footplate can be used as a “pole” to push the footplate away from the conjunctiva and into the fornix space (Fig. 8). A gloved finger is used to fish the footplate and short length of tubing out of the fornix and remove it.

Occasionally, the footplate will remain buried in the conjunctival tissues. In these instances,

sometimes the attached tubing can be used to pull the footplate out through the skin exit hole. Alternatively, the exit site in the eyelid skin can be infiltrated with a small amount of local anesthetic, and a simple cutdown surgery can be performed around the tubing stump to retrieve the footplate and associated remnant.

### 3. Results

Both veterinary ophthalmologists and general equine practitioners rely on these devices to treat their most difficult cases, and properly installed systems usually work very well in both hospital and field situations. SPL tubes have been left in patients for as long as 10 to 12 weeks. Treatment regimens range from multiple medications injected on an hourly basis for initial treatment of serious problems to treatment that is delivered just a few times a day for issues nearing resolution. The use of SPLs to deliver targeted treatment for serious equine ocular problems has preserved vision and saved thousands of eyes.

#### Complications

Although SPLs are managed in most horses without problems, complications do occur in some patients. The two major issues are iatrogenic corneal ulceration from footplate irritation and lack of patency caused by damage to the tube lumen (breakage or development of small punctures).

Corneal ulceration occasionally occurs after an SPL is placed in the upper lid if the device is not inserted deep in the fornix and the footplate rubs against the cornea. It can also occur if the footplate is not snug against the conjunctiva. Removal and replacement of the SPL is necessary to stop further mechanical irritation. A new SPL should be placed and firmly secured to avoid SPL-associated corneal trauma. The second SPL is often placed in the ventronasal aspect of the lower lid because at this site, the nictitans provides a protective barrier between the footplate and the cornea. Ulcers associated with lavage tube irritation are often very slow to heal; choice of treatment medication is dependent on analysis of cytology and culture of the ulcer bed.

Although the silicone tubing of an SPL is quite strong, it can break or develop leaks if the horse snags it on an object. Breaks will be obvious, but leaks may not be noticed immediately. The person treating the horse should be suspicious that the system is not working if a horse stops reacting when enough of an air bolus is injected to push medication into the tear film—the lack of a reaction may indicate that the medication is leaking out of the tube before it reaches the globe surface.

A simple method to check for patency is to tear off a small piece of a fluorescein dye strip and mix it with saline solution. One to 2 mL of the dyed saline is then flushed through the tube. The tear film will turn green as the dye/saline mixture exits the eyelid if the tube is patent. If the tube is leaking, the tear

film will remain clear, but the dyed saline mixture will leak from the damaged part of the tube.

SPL tubing that breaks or tears near the withers can be repaired by simply shortening the tube. The open end of the tube is flushed with a quantity of 1:50 betadine/saline antiseptic, and a new catheter and cap are inserted. An injection port assembly is created as described above and taped and sutured to a more proximal braid.

SPL tubing that breaks near the ear or above the eyelid can be repaired with the use of a 20-gauge catheter as a splice to connect the two separated ends (Fig. 9A–D). The catheter is inserted into one end of the broken tubing, with the stylet retracted slightly back into the catheter lumen. The tubing is “shimmied” over half of the catheter length. The stylet is then removed, and the hub of the catheter is cut off. Half the Teflon catheter is exposed beyond the section that is sleeved with one end of the broken SPL tubing. The other end of the SPL tubing is then carefully pushed over the exposed catheter. This is somewhat difficult without the use of a stylet but can be done with a light touch and a little patience. When both of the broken ends of silicone tubing meet in the center of the catheter tubing, a small piece of white tape is wound around the junction to secure the splice. Patency of the spliced segment is tested with a saline flush, which should pass through the catheter lumen. The section of spliced tubing is then secured to the face or neck crest with a sutured tape wing.

### 4. Discussion

Horses diagnosed with deep stromal or melting ulcers and stromal abscesses usually require an SPL to deliver the intense treatment that is required to save the eye and preserve vision. Horses with conditions such as severe uveitis or indolent ulcers may also benefit from an SPL when the problem is very painful or requires prolonged therapy. Many of these cases can be handled effectively in the field. However, some cases are best referred—even when a practitioner has the skills to insert an SPL, optimum outcome may only be realized with specialist evaluation and hospitalization. Practitioners must consider several factors beyond the simple mechanics of installing an SPL when making clinical decisions on a problem eye. Serious infections and melting ulcers can quickly progress and threaten vision and ocular integrity; therefore, it is important that the treatment plan is based on a comprehensive examination and appropriate diagnostic testing. Practitioners who install SPLs must have skills and experience in assessing such cases and a broad knowledge of rational therapy choices.

SPL insertion is not inexpensive; the kit materials and sedation are costly, and the process of placing and securing the tube is somewhat time-consuming. Owners who bring their horses to a referral facility are prepared for significant expense and readily give permission for SPL placement. However, the first



veterinarian who sees the case usually does the assessment at the home stable. In these settings, owners are often unwilling to authorize tube placement because of the expense and the idea of “a tube in the eyelid.” A common response when an SPL is advised is, “Let me just try to treat this myself for a few days.”

That approach may be acceptable for a simple shallow corneal ulcer in a cooperative horse, but whenever a serious vision-threatening condition is diagnosed, the veterinarian must act as a strong advocate for the horse and recommend immediate SPL insertion. Corneal infections and deep stromal defects respond best if intense treatment is instituted right after initial diagnostics are completed, and an SPL is the key element for safe administration of effective therapy. Owners who decline tube placement often change their minds several days later when the treatments are not reaching the eye consistently, the horse has become unmanageable, and they are exhausted from trying to comply with the rigorous treatment schedule. At this point, the total management cost may actually increase because of progression of disease in the face of ineffective treatment, or it may be too late to initiate effective therapy.

Another element to consider in managing serious ocular problems in an ambulatory setting is that there must be sufficient manpower to carry out the prescribed treatment schedule; treatment may need to be delivered through the SPL six to 12 times per day. If the desired schedule cannot be delivered at the home barn, referral to a full-service hospital



Fig. 10. Horses can be successfully treated on the farm with the use of aids such as fly masks and/or neck covers to protect the SPL.

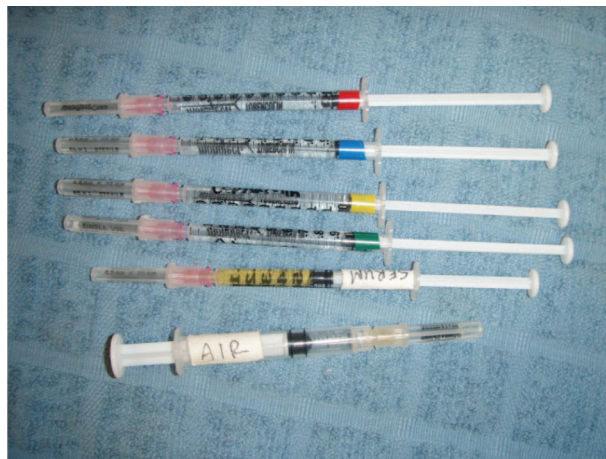

Fig. 11. Colored tape is an effective way to label medication syringes and help caretakers keep track of treatments.

should be encouraged. If referral is not an option, the clinician should stress that having the tube in place is only as useful as the number of times it is used to actually treat the horse.

The author has installed and managed SPLs for a variety of problems in horses of all breeds and ages. Although some of these patients were hospitalized, the majority were treated on the farm (Fig. 10). Stall rest was usually prescribed during the early phase of treatment, but horses that had an SPL in place for several weeks were usually allowed turnout, and some were ridden lightly.

Several simple strategies can be recommended to keep an SPL intact, clean, and protected at home:

- Securing each tape wing on the face with four sutures helps ensure that the wing will stay in place for several weeks when veterinary oversight is infrequent.
- White adhesive tape wraps around the base of each mane braid to help the braids stay tight and keep the SPL tubing close to the crest.
- A plastic bag taped over the injection port assembly keeps the port clean and protected, especially if the catheter cap comes off the catheter. Treatment injections can be done directly through the plastic bag wall, and the bag can be replaced as needed.
- Fly masks provide helpful covers to protect the periocular region and cover the tubing that is exposed on the face. The author rarely uses hoods with hard plastic cups but advises fly masks for the majority of patients.
- Stretchy nylon hoods that cover the head and neck (known as “sleazy sleepwear,” made by a variety of manufacturers) may also protect the SPL from stable or pasture trauma.
- Stalls and paddocks should be inspected for any hooks, nails, or other elements that might snare the tubing: all such items should be

removed or taped over. J-shaped hooks at the base of bucket handles should be taped up.

- Solitary turnout is best because pasture mates may pull at SPL elements and damage them.

Even though the technical process of injecting medication through an SPL is simple, many horses are still difficult to treat because of their temperament or ocular pain. A multidose medication schedule can also be confusing. Several “practice tips” are listed below to help caretakers or technicians manage the treatment plan:

- Medication syringes can be labeled with a thin strip of colored tape for easy distinction of different products (Fig. 11).
- A blank “treatment spreadsheet” that is laid out in grid form with spaces for up to six medications should be issued to the caretaker. This can be stored on the ambulatory computer and emailed or pre-printed. A checkbox system will clarify multidrug treatment regimens and keep track of compliance.
- Horses that react strongly when medication contacts the tear film may become more cooperative if a small treat (sliced carrot, peppermint, gingersnap) is given before and after the process.
- Caretaker “burnout” is a threat to successful therapy. Time spent explaining possible consequences of treatment lapses pays off.
- Digital photography is an invaluable owner education and compliance aid.<sup>4</sup> Sharing images with caretakers will inspire the caretakers to continue with a challenging medication schedule, particularly if sequential images demonstrate positive progress.

Finally, clinicians must make good decisions on when to remove the SPL. Generally, all surface ocular problems must be treated until the corneal surface has epithelialized and the stromal bed has begun to fibrose. Recheck visits with careful examination of the cornea, coupled with administration of surface ocular stains, will be required to assess the status of healing. However, a clinician may want to stop therapy but still may be uncertain about whether the condition is truly healed. In these cases, the tube may simply be left in place for an additional 5 to 7 days. If the condition remains stable, the tube then can be removed, but if there are any negative developments, the SPL is in place and can be used again for further treatment.

## 5. Conclusions

Lavage systems are essential tools for the management of serious ocular disease because they provide an easy, safe means to deliver ocular medications in patients with painful ocular problems. Rational medication selection for individual cases depends on the results of a thorough ocular examination coupled with appropriate diagnostics and any indicated stall-side ocular therapy or procedures. Clinicians who use SPLs to treat major ocular problems in ambulatory practice must have strong skills in ophthalmic examination and have a thorough understanding of corneal disease and ophthalmic pharmacology. Caretakers who use SPLs to deliver complex treatment schedules must dedicate sufficient time to deliver the treatment schedule as prescribed.

Horses tolerate SPLs very well, and the systems may be maintained for months if necessary. The most common complication noted is external trauma to the tube that causes leaks or breaks. Lavage tubing that breaks or develops a hole can be repaired by shortening or splicing the tubing. Lavage system damage from pasture, stall, or patient trauma can be minimized by the use of suture and tape to secure the system to the patient and by external head and neck covers such as fly masks and hoods.

Insertion of an SPL is a simple technique that all equine practitioners can master. This report has outlined numerous tips for installation and management of SPLs that can be implemented in both hospital and ambulatory settings.

## References and Footnotes

1. Sweeney CR, Russell GE. Complications associated with use of a one hole subpalpebral lavage system in horses: 150 cases (1977–1996). *J Am Vet Med Assoc* 1997;211:1271–1274.
2. Giuliano EA, Maggs DJ, Moore CP, et al. Inferomedial placement of a single-entry subpalpebral lavage tube for treatment of equine eye disease. *Vet Ophthalmol* 2000;3:153–156.
3. Jacobi S, Townsend WM, Bolin CA. Proliferation of *Streptococcus zooepidemicus* and *Pseudomonas aeruginosa* within a simulated subpalpebral lavage flushed with equine serum. *Vet Ophthalmol* 2009;12:343–9.
4. Dwyer, AE. How to take digital photographs of equine eyes in practice, in *Proceedings*. Am Assoc Equine Pract 2010;228–237.

<sup>a</sup>Mila International, Erlanger, KY 41018, and Jorgensen Laboratories, Loveland, CO 80538.

<sup>b</sup>Mila International, Erlanger, KY 41018, <http://milainternational.com>.

<sup>c</sup>Champagne Pet Products, Southampton, MA 01073.

<sup>d</sup>Dr Brian Gilger, Personal communication.

<sup>e</sup>Infu-Disk, Mila International, Erlanger, KY 41018.