

# Compendium

## Equine Distal Limb Wounds: New and Emerging Treatments

**Christopher G. Alford, DVM, MS, DACVS**

Morrie Waud Equine Center  
Delavan, Wisconsin

**Fred J. Caldwell, DVM, MS, DACVS**

**Reid Hanson, DVM, DACVS, DACVECC**

JTV Teaching Hospital  
Auburn University, Alabama

**Abstract:** Distal limb wounds occur commonly in horses, and treatment can be frustrating for owners and veterinarians. Caring for these wounds is often very expensive, labor intensive, and prolonged. Many commercial products and clinical techniques have been developed to help treat these wounds. Healing of these wounds depends on many factors. With proper wound evaluation and treatment, affected horses can return to function sooner than in the past.

Horses frequently sustain traumatic injuries to the distal limbs, often resulting in wounds that require extended management for adequate healing. Care of these wounds often requires immobilization and confinement to facilitate healing, delaying the patient's return to regular activity. The cost of long-term bandaging and extended follow-up care routinely exceeds the cost of initial treatment. Therefore, efforts to facilitate healing of these difficult wounds are increasing.

Distal limb wounds often result from trauma due to objects in a horse's environment. Because of the equine fight-or-flight instinct, some injuries are unavoidable despite the best efforts of the most cautious horse owners. Distal limb wounds often result in a large loss of soft tissue, precluding primary closure. When possible, primary closure is ideal but is prone to failure because of excessive contamination, limited availability of overlying soft tissue, and dehiscence due to poor blood supply or excessive tension and/or motion at the wound edges. In one equine study, primary closure of distal limb wounds without dehiscence was successful in 24% to 26% of cases.<sup>1</sup> Compared with wounds elsewhere on the body, wounds on the distal limbs heal slower due to a longer preparatory phase and a greater degree of wound retraction.<sup>2,3</sup> Most distal limb wounds must heal by second intention, requiring prolonged, intensive wound care to obtain a desirable outcome. Therefore, new and improved wound management products and techniques are needed.

Proper planning and treatment during an initial examination can be significant for successfully resolving distal limb injuries and hastening a patient's return to normal activity. Practitioners should perform a complete physical examination of a patient with

a distal limb wound before focusing on the wound or sedating the patient. Then the wound should be cleaned and aseptically prepared before it is thoroughly palpated and diagnostically imaged.

### Debridement Mechanical Debridement

Initial debridement should focus on reducing the presence of necrotic tissue and the bacterial load within the wound. Using a sterile scalpel blade or scissors for mechanical debridement offers the most control. However, sharp debridement is not always possible to the extent necessary, especially in a standing horse. Sharp debridement may be facilitated with the use of general anesthesia; however, the benefit of additional debridement should be weighed carefully against the risk of complications associated with anesthesia and with recovery on an already compromised limb.

While most practitioners are familiar with sharp debridement techniques using a blade or scissors, carbon dioxide (CO<sub>2</sub>) lasers can also be used for debridement, as first described for equine wounds more than a decade ago.<sup>4</sup> CO<sub>2</sub> lasers are increasingly available to general practitioners and can be effective when used alone or in conjunction with traditional means of sharp debridement. The CO<sub>2</sub> laser allows practitioners to superficially vaporize and ablate damaged and necrotic tissue. Because of the relatively minimal penetration of the CO<sub>2</sub> laser, it is less likely than other lasers to cause collateral damage to surrounding healthy tissue. Although lasers are precise, they require steady control: deeper wound tissue should not be exposed to the heat of the laser.<sup>5</sup> Compared with CO<sub>2</sub> lasers, neodymium-yttrium-aluminum-garnet

(Nd:YAG) and gallium-aluminum-arsenide (GAA) lasers penetrate deeper into tissue, possibly damaging tissue beyond the debridement site. Using a CO<sub>2</sub> laser does not completely sterilize a wound but may eliminate many microorganisms; compared with sharp mechanical debridement, the use of a CO<sub>2</sub> laser produces minimal hemorrhage.<sup>5,6</sup>

The use of commercial antimicrobial bandaging materials alone or with wet-to-dry dressings (in which a moistened gauze sponge is placed over the wound) or wet-to-wet dressings (in which a moistened sponge is placed over a moistened wound) is convenient for mechanical debridement and inhibiting microbial growth. A 0.2% polyhexamethylene biguanide product (PHMB; Kendall Kerlix AMD, Tyco Healthcare, Mansfield, MA) and a silver-coated dressing (Silverlon, Argentum Medical, Chicago, IL) are popular antibacterial dressings. Although these materials are unlikely to produce a significant antibacterial effect within wounds, the manufacturers claim that their products substantially decrease secondary contamination of wounds during healing. Because secondary infection is a well-known cause of delayed healing,<sup>7</sup> elimination of opportunistic infection should hasten recovery.

## Enzymatic Debridement

Many commercial advances in wound care have involved chemical and enzymatic wound debridement products. Pure chemical debridement involves hydrogen peroxide or hypotonic or hypertonic saline. Hypotonic and hypertonic dressings and solutions use the osmotic gradient to lyse and destroy bacterial cells. While effective, this mechanism of action is nonselective, possibly destroying fibroblasts in the initial healing process and slowing wound healing.<sup>8,9</sup> Overall chemical debridement is nonselective; therefore, it is generally reserved for initial management of severely contaminated wounds.

Necrotic tissue can be selectively removed using enzymatic debridement agents. Serum leakage from a wound combined with bacterial biofilm produces a proteinaceous layer on the wound surface, inhibiting penetration of topical and systemic antibiotics. Enzymatic debridement selectively breaks down the biofilm to allow effective systemic or topical antibiotic therapy.<sup>10</sup> Many commercial formulations of enzymatic debridement agents are readily available to equine practitioners and owners. Products containing streptokinase, trypsin, fibrinolysin, protease, or

collagenase work in a similar manner; however, recent laboratory and human research suggests that the use of collagenase is more likely to result in a clean wound.<sup>11,12</sup> While enzymatic debridement shows promise for eliminating necrotic debris and bacteria, this method has limitations in treating large areas of contamination or necrosis and the available products for this method are considerably more expensive than those for other methods. Furthermore, while enzymatic debridement has been shown to be selective, resulting in minimal damage to underlying healthy tissue, use of this method could cause collagenase and fibrinolysin to delay healing by inhibiting the cellular products produced by affected tissues for wound repair.

## Autolytic Debridement

Perhaps the most significant development in wound debridement therapy is facilitation of autolytic debridement by maintaining wounds in a moist environment. While this technique has been used for decades, it has recently gained more widespread acceptance as understanding of healing at the cellular level increases. Autolytic debridement is accomplished by allowing wound exudate—which is rich in endogenous enzymes, growth factors, and cytokines—to act on the wound and provide an optimal environment for healing. The collective components of wound exudate stimulate the migration of fibroblasts, epithelial cells, vascular tissues, neutrophils, and macrophages. In turn, neutrophils and macrophages control bacterial contamination of the site.<sup>13</sup>

While the patient provides the active components for autolytic debridement, proper preparation and bandaging materials and techniques are essential for maintaining an optimal environment for healing. Autolytic debridement appears to be very selective and effective at the microscopic level but largely ineffective in the presence of gross amounts of necrotic debris. Therefore, another type of debridement (e.g., sharp debridement) may be required to prepare the wound before autolytic debridement is used.<sup>14</sup> In general, semioclusive or nonocclusive dressing materials are preferred for maintaining an optimal balance of gas permeability and moisture in the wound bed. Occlusive wound dressings offer an excellent means of retaining wound exudate and preventing opportunistic bacterial infections; however, these dressings allow little to no permeability of oxygen, which is required for aerobic metabolism necessary for the initial growth and the regeneration of tissue with a compromised blood supply.<sup>15</sup> Autolytic debridement is very cost effective and requires minimal labor and expertise. When it is used for wounds that are not heavily infected or composed of devitalized tissue, excellent results are generally obtained.<sup>8</sup>

Acemannan hydrogels show promise for speeding healing of wounds by helping to facilitate autolytic debridement. Acemannan hydrogels are three-dimensional, water-swollen sheets of gel-like material (**FIGURE 1**) produced from the major carbohydrate fraction of the aloe vera leaf. These products facilitate a moist wound environment and promote collagenase production, facilitating wound debridement.<sup>15,16</sup> However, because these wound dressings are nonadherent and occlusive, they should be reserved for use on less exudative wounds<sup>15</sup> or over denuded bone. In human

### For More Information

#### Christopher G. Alford, DVM, MS, DACVS

Morrie Waud Equine Center  
N6255 Church Road  
Delavan, WI 53115  
E-mail: chrisalford@hotmail.com

#### Fred J. Caldwell, DVM, MS, DACVS

JTV Teaching Hospital  
1500 Wire Road  
Auburn University, AL 36849  
E-mail: caldwfj@auburn.edu

#### Reid Hanson, DVM, DACVS, DACVECC

JTV Teaching Hospital  
1500 Wire Road  
Auburn University, AL 36849  
E-mail: hansorr@auburn.edu



**Figure 1.** Acemannan hydrogel before application to a wound.



**Figure 2.** Calcium alginate wound dressing before application to a wound.

clinical trials, hydrogels have been shown to be superior to conventional bandage materials,<sup>17</sup> supporting the view that a moist wound environment is beneficial. Acemannan is derived from aloe vera  $\beta$ -(1,4)-acetylated mannan and has been shown to stimulate macrophages by promoting cytokine production, nitric oxide release, surface molecule expression, and cell morphologic changes,<sup>18</sup> resulting in secretion of interleukin 1 and tissue necrosis factor  $\alpha$  as well as stimulation of angiogenesis and epidermal growth.<sup>19</sup> Although no studies have evaluated these effects in horses, we have had good results when using acemannan products for wound care in clinical cases. Acemannan has also been shown to be beneficial when used in canine patients.<sup>20</sup> Keeping a wound moist also encourages epithelialization.

The many commercial acemannan formulations include hydrogels, gels, and sprays. In our opinion, these products seem to perform very well. The spray application seems to be very effective at debriding and cleaning wounds through three complementary mechanisms of action: (1) the effects of acemannan on wound healing (discussed above), (2) action of a surfactant ingredient, and (3) pressure irrigation. Surfactants help to decrease surface tension between foreign material, bacteria, and healthy tissue, allowing pressure irrigation to efficiently wash away debris. Most commercial spray applications are designed to spray at a pressure of 10 to 15 lb/sq in, which has been described as ideal for irrigation and debridement.<sup>8,14</sup>

Although calcium alginate products act much like hydrogel products, they are initially a dry, three-dimensional fabric that absorbs exudate from a wound to form a gel-like substance (**FIGURE 2**). This substance is known to have hemostatic properties and to be bioabsorbable within a wound.<sup>21</sup> Calcium alginate products are most commonly used in the early management of open wounds, which tend to have more exudate, debris, and hemorrhage following extensive contamination and sharp debridement. However, because of the absorptiveness of calcium alginate products, one study using

a porcine model was able to leave them in place for up to 14 days to avoid disturbing reparative tissues and to facilitate healing.<sup>22</sup>

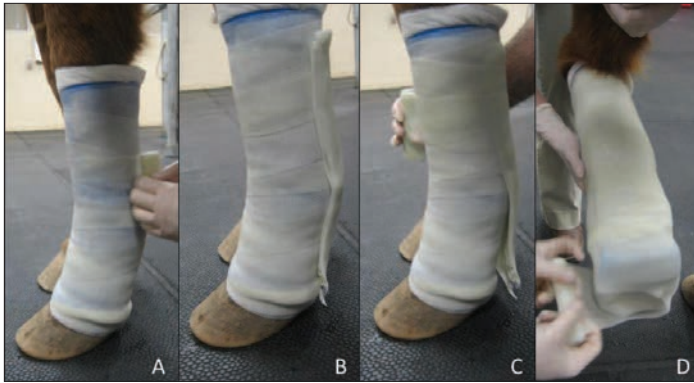
Although autolytic debridement is generally very sparing of healthy proliferative tissue within a wound, this does not necessarily account for bandage changes and removal of wound dressings. Hydrogels tend to have few adhesive properties and therefore do not adhere to and remove healthy tissue, whereas calcium alginate products are completely bioabsorbable. The latter require bandage changes but minimally disturb wounds in the early stages. Research has shown that the use of calcium alginate is well tolerated and results in good epidermal healing<sup>22</sup>; however, these products should be avoided or premoistened for use on drier, minimally exudative wounds.

## Bandaging and Immobilization

Whether to bandage and what type to apply to a distal limb are decisions based on many variables, including cost, amount of immobilization desired, amount of exudate, degree of infection, and the owner's ability to change or assess the bandage. Bandaging has been shown to promote angiogenesis, decrease bacterial load, and reduce limb edema, all of which expedite healing.<sup>23-26</sup>

One of the most common types of bandages is a simple primary dressing, overwrapped by a cotton bandage and compressed with an elastic outer wrapping. While this bandage allows excellent absorption of exudate and is easy to change, it does little to immobilize the wound area, possibly resulting in failure of closure or delayed healing by second intention. Additionally, when wounds of the flexor or extensor tendons are involved, this type of immobilization is insufficient and more rigid bandaging is indicated. A simple bandage can be changed by the owners and, when applied properly, rarely results in bandage sores. Although simple to use and individually inexpensive, these bandages typically require frequent replacement for extended periods, which can become quite costly.





**Figure 3.** Construction of a bandage cast composed of soft casting material and incorporating a rigid palmar/plantar splint. (A) Several layers of soft casting tape are placed over the underlying bandage. (B) A palmar/plantar splint is constructed using a single roll of traditional or rigid casting material. (C) Additional soft casting tape is applied over the limb and the foot (D) to unify the entire cast.

### Splinting

Splints are often incorporated into bandages to help immobilize a wound. Splints are often made from boards, polyvinylchloride (PVC) pipe, heated and molded PVC, or fiberglass casting tape. Properly applied splints offer immobilization that is superior to bandaging alone but inferior to casting. The major benefit of splints is that they can be readily changed by owners who have been properly instructed. Splints tend to become displaced or to turn within a bandage, resulting in a lack of immobilization and potential development of sores. While splints generally provide enough support to wounds involving an extensor tendon,<sup>23</sup> we think that splints are generally not strong enough to support lacerations with flexor tendon involvement.

### Casting

In our opinion, bandage casting<sup>27</sup> is often underused. A bandage cast can be placed directly over the bandages described in this article. In general, bandage casts have the same benefits of bandages but provide superior immobilization and do not require frequent changing. Bandage casts can be left in place for various durations; with proper application and the absence of excessive exudate, bandage casts can generally remain in place for 2 weeks without causing significant pressure sores or other injuries. Two weeks is often enough time for an underlying wound to begin healing, potentially increasing the success of primary closure of a wound. Bandage casts can be made into various lengths: half-limb, full-limb, and phalangeal bandage casts have all been described.<sup>23</sup> We think that it is difficult to achieve adequate immobilization using the same amount of bandage material under a phalangeal cast. Therefore, in some cases, it is necessary to decrease the amount of bandage material under phalangeal casts.

Traditional casting techniques use minimal bandage material or padding under a cast. Although this optimizes immobilization of the limb, when a cast is placed over a wound, even minimal exudate can result in strikethrough—the appearance of blood or wound exudate seeping through the bandage and cast. Strikethrough

indicates worsening of the wound or, potentially worse, the development of a new wound or a pressure sore. While pressure sores appear to be rare with the use of bandage casts,<sup>27</sup> they can occur due to improper cast application or unnoticed wearing or cracking. Therefore, some practitioners may elect to hospitalize casted patients based on an owner's ability to manage and assess a cast daily.

Bandage casts may be readily applied to standing patients. A cast that is too long often causes cast sores at the proximal dorsal interface of the cast and skin. This tends to occur in horses that were under general anesthesia during cast application; once these horses stand, their weight leads to sinking into the cast. Standing horses can complicate cast placement by moving or by failing to cooperate. The decision to place a cast while a horse is standing or recumbent is usually dictated by the debridement and closure of the underlying wound as well as the horse's temperament: if the horse allows debridement and closure of the wound while standing, then the cast can typically be placed while the horse is standing as well. Distally, cast sores tend to develop at the palmar or plantar aspect of the fetlock, specifically at the base of the sesamoid bones. Development of sores can be minimized during cast placement by slightly elevating the heel with a wedge, usually made from a roll of casting material. This produces a more upright posture of the distal limb, transferring the horse's weight down the limb in a straight column and minimizing the weight on the palmar or plantar surface of the fetlock. Even with proper placement of a cast, sores may develop and can become more serious than the original lesion. Therefore, it is imperative to monitor casts closely on a daily basis and examine them for strikethrough, especially at sites prone to sore development. The presence of blood or exudate at the back of the fetlock region warrants immediate removal of the cast for treatment of the underlying sore.

While the initial expense of casting is higher than that of bandaging, casting minimizes the need for bandage changes and subjectively expedites healing. Once the cast is removed, it can be reapplied as a bivalve cast by cutting it medially and laterally to facilitate bandage changes. If the cast is in good condition once the underlying dressing is changed, the two halves can be applied over the new bandage to gradually decrease immobilization of the limb and wound. Typically, one or two layers of an inelastic athletic tape are sufficient to hold the halves of the cast together. Even when the same cast application technique is used and the compression is similar to that of the first application, perfect opposition is usually difficult to achieve because of unavoidable differences in the underlying bandage material and the rigidity of the cast material.

We have used a "hinged" or "soft" bandage cast created from a soft cast material for managing distal limb wounds; the available products are 3M Scotchcast Soft Cast (3M Animal Care Products, St. Paul, MN), Delta-Cast Soft (BSN Medical Inc, Rutherford College, NC), and Cellacast Soft (Activa Healthcare, Staffordshire, UK). This material is applied in the same manner as traditional fiberglass casting tape, but it sets with much less rigidity.

To place this type of cast, the limb is prepared with an underlying bandage as described for a traditional bandage cast, and

several layers of the soft casting material are applied over the bandage (FIGURE 3A). A palmar or plantar splint is made with a single roll of traditional cast material to add rigidity to the cast (FIGURE 3B). Before the splint sets, additional soft cast material is applied over the other layers to finish the cast (FIGURE 3C; FIGURE 3D). It is imperative that this be done in a timely manner before the first layers of soft casting material set in order for all the layers to be incorporated and to set together. The cast is then split laterally with a cast saw either after the cast has set or just before removal. If the cast is split and remains in place, an inelastic or standard porous tape (e.g., Curity Standard Porous Tape, Covidien Animal Health, Mansfield, MA) is applied to maintain the cast's integrity. This type of tape provides good tensile strength within minimal elasticity and is permeable to allow the cast to breathe.

The major advantages of this type of cast are that it offers all the aforementioned benefits of using a bandage cast and also allows bandage changes, if needed. Furthermore, the flexibility of the soft cast material allows the cast to conform easily over new bandage material. Therefore, during cast replacement, soft cast material is more forgiving than the rigid materials in a bivalve cast (FIGURE 4).

## Other Therapies

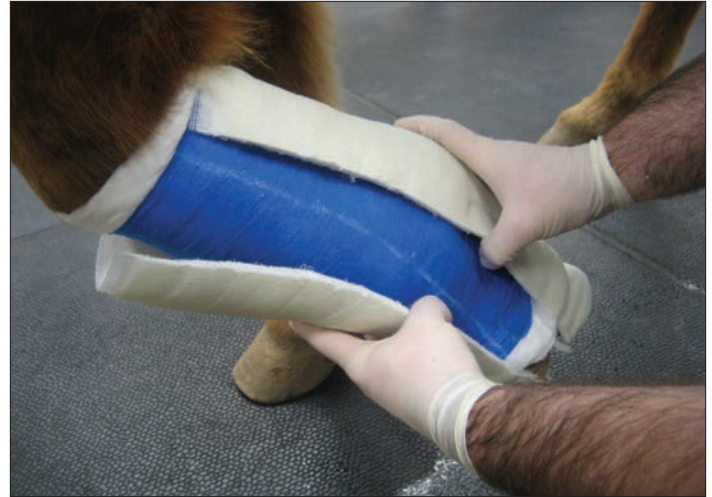In most cases, appropriate debridement followed by proper bandage selection and application result in adequate wound healing. However, in some cases, because return to function and speed of healing are top priorities, adjunct modalities may be warranted. Various skin grafting techniques have been described for treating large or nonhealing wounds and generally require minimal specialized equipment or experience.<sup>28</sup> Preferred techniques vary among practitioners and are based largely on personal experience. Skin grafting has been shown to hasten healing, but new modalities are always being developed and deserve consideration. The following summarizes some of the new and often controversial modalities in wound healing.

### Platelet-Rich Plasma

Commercial products to harvest and concentrate platelets to produce platelet-rich plasma (PRP) are readily available to veterinarians. The use of PRP *in vitro*<sup>29</sup> and *in vivo*<sup>30</sup> has been shown to facilitate and speed healing in equine models by enhancing fibroblast proliferation and migration<sup>29</sup> and by accelerating epithelial differentiation.<sup>30</sup> The use of PRP in clinical or contaminated wounds has not been evaluated, so the effects of these environments on PRP solutions are unknown. Therefore, the use of PRP in a clinical or contaminated wound should likely be reserved until after the wound has been sufficiently debrided. PRP is relatively expensive and may be cost prohibitive; however, the cited experimental models show promise, warranting consideration of the use of PRP in select clinical cases when a fast recovery is a top priority.

### Low-Level Laser Therapy

Low-level laser therapy (LLLT) has been theorized to promote healing and accelerate recovery. Because the results of many studies have been contradictory, it is unclear whether LLLT is beneficial



**Figure 4.** A “hinged” or “soft” bandage cast being removed from a limb. The cast opens laterally and is flexible on the medial side to allow the dorsal aspect of the cast to bend and to be removed or replaced.

to wound healing. At least one study showed no benefit of LLLT in horses,<sup>31</sup> while studies in other species have found that it histologically reduced inflammation and edema and increased collagen synthesis.<sup>32,33</sup> One review that examined 36 human and animal studies with various results was unable to validate the efficacy of LLLT and did not consider it a valuable wound therapy.<sup>34</sup> It has been theorized that the benefits that some researchers obtain with LLLT may result from tissue warming.<sup>5</sup> When considering the use of LLLT, an equine practitioner must weigh the benefit of proposed healing against the potential for disrupting healing tissues if the wound is bandaged.

### Hyperbaric Oxygen

The use of hyperbaric oxygen has gained popularity for facilitating wound healing. Hyperbaric oxygen has been used in humans to treat numerous conditions, including wounds. The promotion of wound healing through the use of hyperbaric oxygen involves several pathways. Intermittent correction of wound hypoxia decreases inflammation, increases fibroblast proliferation and collagen production, increases the ability of leukocytes to kill bacteria, promotes angiogenesis, and increases the rate of epithelialization.<sup>35</sup> Similar to PRP therapy, hyperbaric oxygen therapy is often cost prohibitive and may be considered excessive for treating most equine distal limb wounds; however, unlike PRP therapy, hyperbaric oxygen therapy usually involves several treatments, increasing hospitalization time and cost. However, in some cases, hyperbaric oxygen therapy is warranted and appears to be beneficial. The costs of purchasing and maintaining a hyperbaric oxygen unit tend to be prohibitive for most practices; however, an increasing number of equine facilities are offering this therapy, making referral a valid option.

### Shock Wave Therapy

Extracorporeal shock wave therapy (ESWT) is gaining popularity for promoting healing of soft tissue injuries involving tendons or

ligaments responsible for lameness. Although its mechanism of action is poorly understood, ESWT has been shown to decrease the mean healing time (from 90 to 76 days) of fresh distal limb wounds in an equine model.<sup>36</sup> A limited number of ESWT studies have been performed in horses, and no therapeutic protocol regarding duration, strength, or number of pulses has been developed. However, ESWT units are becoming more prevalent in equine practices and the potential of ESWT to expedite wound healing may warrant its use.

### Conclusion

Distal limb wounds occur commonly in horses, and treatment can be frustrating for owners and veterinarians. Complications and delays in healing are frequent and often necessitate a change in the treatment plan. However, if damage to synovial structures or flexor tendons is not present, the prognosis for affected patients is generally favorable. The goal of treatment is often not only to return an equine patient to soundness but also to minimize the patient's down time and the associated costs of extensive after-care and bandaging.

Cost should always be considered when a treatment plan is being determined; however, many treatments that are initially expensive are often justified by their ability to reduce healing time. While many new products and techniques appear to be useful for managing distal limb wounds, perhaps the most important factor in determining success is a thorough examination and assessment. No treatment is appropriate for all wounds; therefore, a complete initial evaluation coupled with periodic follow-up evaluations can ensure that equine practitioners use the most appropriate treatment at the earliest possible time to minimize the recovery period.

### References

1. Wilmlink J, van Herten J, van Weeren P, et al. Retrospective study of primary intention healing and sequestrum formation in horses compared to ponies under clinical circumstances. *Equine Vet J* 2002;34:270-273.
2. Jacobs K, Leach D, Fretz P, et al. Comparative aspects of the healing of excisional wounds on the leg and body of horses. *Vet Surg* 1984;12:83-90.
3. Wilmlink J, Stolk P, Van Weeren P, et al. Differences in second-intention wound healing between horses and ponies: macroscopic effect. *Equine Vet J* 1999;31:53-60.
4. Palmer S. Instrumentation and techniques for carbon dioxide lasers in equine general surgery. *Vet Clin North Am Equine Pract* 1996;12:397.
5. Sullins K. Lasers: effects on healing and clinical applications. In: Stashak TS, Theoret CL, eds. *Equine Wound Management*. 2nd ed. Ames, IA: Wiley-Blackwell; 2008.
6. Sullins K. Lasers and wound healing: practical uses. *Clin Tech Equine Pract* 2004;3:182-187.
7. Stashak T. Selected factors that negatively impact healing. In: Stashak TS, Theoret CL, eds. *Equine Wound Management*. 2nd ed. Ames, IA: Wiley-Blackwell; 2008.
8. Hendrickson D. Wound preparation, cleaning, and debridement. In: Hendrickson DA, ed. *Wound Care Management for the Equine Practitioner*. Jackson Hole, WY: Teton NewMedia; 2005.
9. Stashak T, Farstedt E. Update on wound dressings: Indications and best use. In: Stashak TS, Theoret CL, eds. *Equine Wound Management*. 2nd ed. Ames, IA: Wiley-Blackwell; 2008.
10. Wilson D. Principles of early wound management. *Vet Clin Equine* 2005;21:45-62.
11. Glyantsev S, Adamyan A, Sakharov Y. Crab collagenase in wound debridement. *J Wound Care* 1997;6:13-16.
12. Mosher B, Cuddigan J, Thomas D. Outcomes of 4 methods of debridement using a decision analysis methodology. *Adv Wound Care* 1999;12:81-88.
13. Hendrickson D. Second intention healing. In: Hendrickson DA, ed. *Wound Care Management for the Equine Practitioner*. Jackson Hole, WY: Teton NewMedia; 2005.
14. Hendrickson D. Management of superficial wounds. In: Auer JA, Stick JA, eds. *Equine Surgery*. 3rd ed. Philadelphia, PA: WB Saunders; 2006.
15. Gomez J, Hanson R. Use of dressings and bandages in equine wound management. *Vet Clin Equine* 2005;21:91-104.
16. Theoret C. What's new and innovative in wound management: problems and solutions. *Proc Am Assoc Equine Pract* 2006;265-269.
17. Smith R, Rushbourne J. The use of solugel in the closure of wounds by secondary intention. *Primary Intention* 1994;1:14-17.
18. Zhang L, Tizard IR. Activation of a mouse macrophage cell line by acemannan: the major carbohydrate fraction from aloe vera gel. *Immunopharmacology* 1996;35:119-28.
19. Swaim S, Gillette R. An update on wound medications and dressings. *Compend Contin Educ Pract Vet* 1998;20:1133-1144.
20. Swaim S, Vaughn D, Kincaid S, et al. Effect of locally injected medications on healing pad wounds in dogs. *Am J Vet Res* 1996;57:394-399.
21. Blaine G. Experimental observations on absorbable alginate products in surgery. *Ann Surg* 1947;125:102-107.
22. Barnett S, Varley S. The effects of calcium alginate on wound healing. *Ann R Coll Surg* 1987;69:153-155.
23. Gomez J, Stashak T. Bandaging and casting techniques for wound management. In: Stashak TS, Theoret CL, eds. *Equine Wound Management*. 2nd ed. Ames, IA: Wiley-Blackwell; 2008.
24. Stashak T. Selected factors that affect wound healing. In: Stashak TS, ed. *Equine Wound Management*. Philadelphia, PA: Lea & Febiger; 1991.
25. Knighton D, Silver I, Hunt T. Regulation of wound-healing angiogenesis. Effect of oxygen gradients and inspired oxygen concentration. *Surgery* 1981;90:262.
26. Wollen N, DeBowes R, Liepold H. A comparison of four types of therapy for the treatment of full thickness wounds of the horse. *Proc Am Assoc Equine Pract* 1987;569-576.
27. Hogan P. How to make a bandage cast and indications and indications for its use. *Proc Am Assoc Equine Pract* 2000:150-152.
28. Schumacher J. Skin grafting. In: Auer JA, Stick JA, eds. *Equine Surgery*. 2nd ed. Philadelphia, PA: Saunders; 2006.
29. Tablin F, Walker N, Hogle S, et al. Assessment of platelet growth factors in supernatants from rehydrated freeze-dried equine platelets and their effects on fibroblasts in vitro. *Am J Vet Res* 2008;69:1512-1519.
30. Carter C, Jolly D, Worden C, et al. Platelet-rich plasma gel promotes differentiation and regeneration during equine wound healing. *Exp Mol Pathol* 2003;74:244-255.
31. Peterson S, Botes C, Oliver A, et al. The effect of low level laser therapy (LLLT) on wound healing in horses. *Equine Vet J* 1999;31:228-231.
32. Medrado A, Pugliese L, Reis S, et al. Influence of low level laser therapy on wound healing and its biological action upon myofibroblasts. *Laser Surg Med* 2003;32:239-244.
33. Ghamsari S, Taguchi K, Abe N, et al. Evaluation of low level laser therapy on primary healing of experimentally induced full thickness teat wounds in dairy cattle. *Vet Surg* 1997;26:114-120.
34. Lucas C, Criens-Poublon L, Cockrell C, et al. Wound healing in cell studies and animal model experiments by low level laser therapy; were clinical studies justified? A systematic review. *Laser Med Sci* 2002;17:110-134.
35. Jain K. HBO therapy in wound healing, plastic surgery, and dermatology. In: Jain KK, ed. *Textbook of Hyperbaric Medicine*. 4th ed. Cambridge, MA: Hogrefe and Huber; 2004.
36. Morgan D, McClure S, Yager M, et al. Effects of extracorporeal shock wave therapy on wounds of the distal portion of the limbs in horses. *J Am Vet Med Assoc* 2009; 234:1154-1161.