

LANDMARKS

For this block there are four nerves to block: deep and superficial branches on both the medial and lateral aspects of the limb. The deep nerves course between the splint bones and the cannon bone on the axial surface of the splint bones. These are blocked just distal to the end of the splint bone using 25ga needle. The superficial nerves course between the suspensory ligament and the deep flexor tendon but can be on either side of a fascial reflection: to block these, you need to fan the needle (move it around) with sufficient local anesthetic to cover moderate sized area.

NEEDLE SIZE AND LENGTH & VOLUME OF LA

5/8 inch
25 gauge
1-2 ml at each site

AREA DESENSITIZED

Anesthesia of the skin over the dorsal aspect of the proximal phalanx of the fetlock indicates that the low palmar block was successful .

INDICATIONS

Used to Localize pain that is causing lameness that has not improved after anaesthetizing the PD nerves at the level of the base of the proximal sesamoid bones or to desensitize the foot or pastern for surgery

DISADVANTAGES

Palmar pouches of the fetlock joint can be entered inadvertently

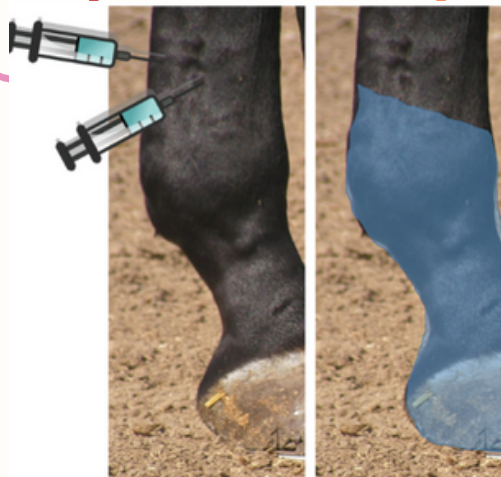
ADVANTAGES

Localizes pain causing lameness that has not improved after anesthetizing the palmar digital nerves at the level of the base of the proximal sesamoid bones.

TESTING

Anesthesia of the skin over the dorsal aspect of the proximal phalanx of the fetlock indicates that the low palmar block was successful . The horse may retain some cutaneous sensation over the dorsal aspect of the fetlock due to sensory innervation from a branch of the medial cutaneous antebrachial nerve

L4PNB



ONSET & DURATION

Drug	Onset of Action (min)	Duration of Action (min)
Lidocaine	5-15	60-120
Mepivacaine	5-30	90-180
Bupivacaine	15-45	180-480