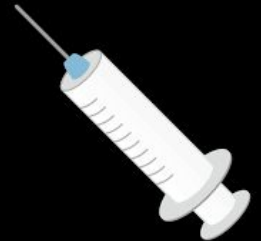

Advantages & Disadvantages of Nerve Blocks in Equine Medicine



COMMON NERVE BLOCKS IN EQUINE

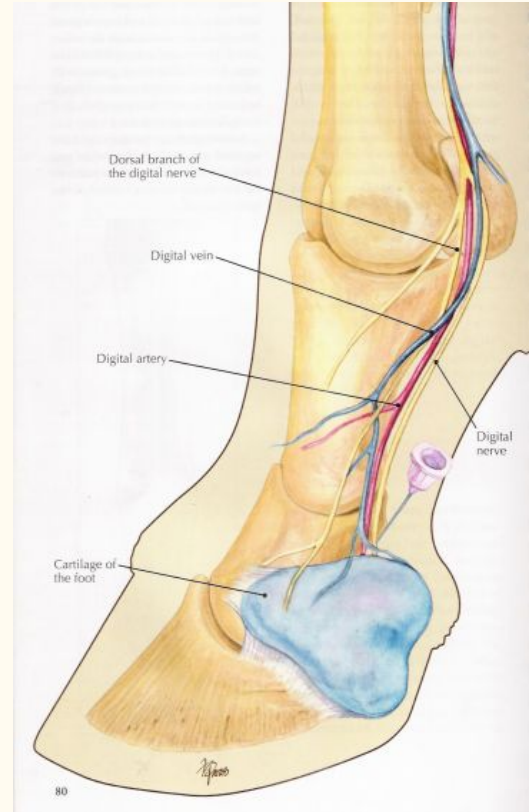
- Palmar Digital (Heel block)
- Abaxial Sesamoid (Pastern/foot block, High Palmar digital block)
- Low Palmar (Fetlock block, Low 4 point block)
- High Palmar (Metacarpal, High 4 point block)

ADVANTAGES OF PALMAR DIGITAL BLOCK

Blocks the palmar/plantar digital nerves innervating the palmar/plantar (heel) aspect of the foot

Desensitizes:

- The entire sole
- Navicular apparatus
- Soft tissues of heel
- Entire distal interphalangeal joint (coffin joint)
- Distal portion of the deep digital flexor tendon
- Distal sesamoidean ligaments



ADVANTAGES OF PALMAR DIGITAL BLOCK

Conditions blocked:

- Shoeing problems
- Cruising of palmar(plantar sole
- Thrush
- Navicular disease
- Navicular fractures
- Palmar fractures of P3
- Digital cushion and bulb lesions

DISADVANTAGES OF PALMAR DIGITAL BLOCK

- Dorsal portion (toe) of the foot is unaffected

Partially blocked

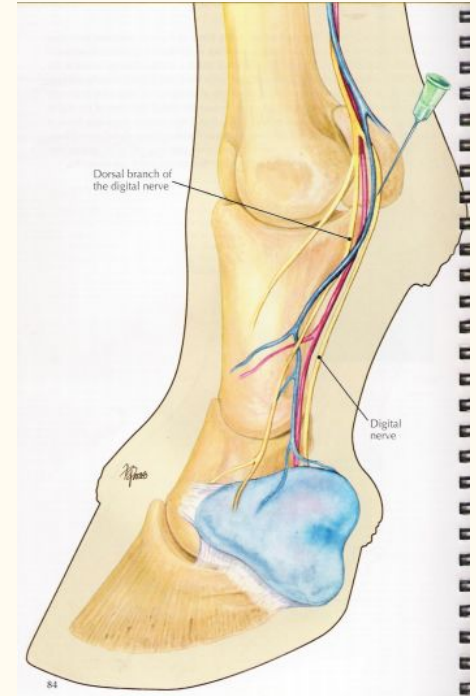
- Coffin joint problems (synovitis, arthritis)
- Laminitis

ADVANTAGES OF THE ABAXIAL SESAMOID BLOCK

Blocks the pastern and entire foot

Desensitizes

- Foot
- Middle phalanx
- Proximal interphalangeal joint
- Distopalmar aspects of the proximal phalanx
- Distal portion of the superficial and deep flexor tendons
- Distal sesamoidean ligaments
- Digital annular ligament
- Sometimes the palmar portion of the metacarpophalangeal joint



ADVANTAGES OF THE ABAXIAL SESAMOID BLOCK

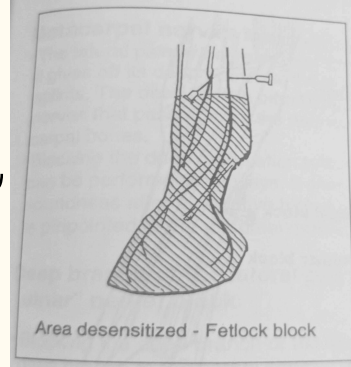
Conditions blocked:

- Pastern joint (synovitis, degenerative joint disease/DJD)
- Pastern area (distal sesamoidean strain, lacerations)
- Coffin joint (synovitis, DJD, subchondral bone cysts)
- Toe of foot (bruises, abscesses, canker, laminitis, seedy toe, shoeing problems, fracture of P3)
- Heel (ruled out with heel block)

DISADVANTAGES OF THE ABAXIAL SESAMOID BLOCK

- Performing the nerve block at the base of the proximal sesamoid bones decreases the likelihood of partially desensitizing the metacarpal joint.
- Using a small volume of local anesthetic solution and directing the needle distally, rather than proximally, may also decrease the likelihood of partially anesthetizing the metacarpal joint

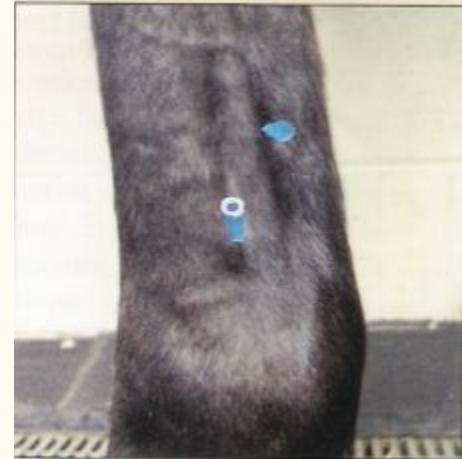ADVANTAGES OF THE LOW PALMAR BLOCK



- Localizes pain causing lameness that has not improved after anesthetizing the palmar digital nerves at the level of the base of the proximal sesamoid bones

Desensitizes :

- The foot or pastern regions for surgery
- The superficial and deep digital flexor tendons
- Distal aspect of the branches of the suspensory apparatus



DISADVANTAGES OF THE LOW PALMAR BLOCK

- Inadvertent penetration of the deep flexor tendon sheath is high
- Potential hemorrhage from medial palmar vein and artery

ADVANTAGES OF HIGH PALMAR BLOCK

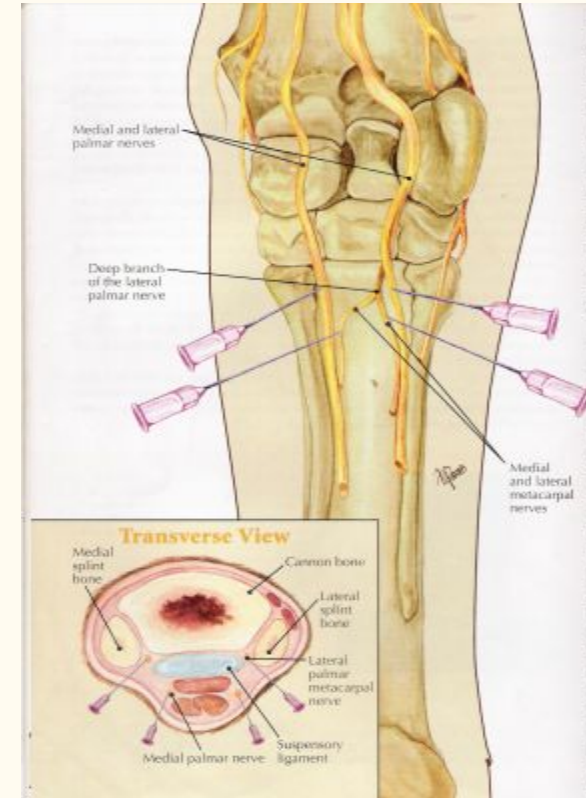
Blocks the metacarpal regions except the origin of the suspensory ligament, inferior check ligament of deep digital flexor and the proximal splints and cannon.

- High palmar block
 - Anesthetizes the superficial metacarpal structures by blocking the medial and lateral palmar nerves at the proximal metacarpus
- High metacarpal block
 - Anesthetizes the metacarpal nerves therefore most of the suspensory ligament and the interosseous ligaments of metacarpal bones

ADVANTAGES OF HIGH PALMAR BLOCK

Conditions blocked

- Bowed tendon (tendonitis) and tenosynovitis
- Stress fractures of cannon bone (McII)
- Bucked shins
- Splint bone fractures
- Middle and low desmitis of suspensory ligament



DISADVANTAGES OF HIGH PALMAR BLOCK

Conditions not blocked

- High suspensory desmitis
- Splints
- High splint fractures
- Inferior check ligament

RESOURCES:

- Moyer WW. Guide to equine joint injection and regional anesthesia. Chadds Ford: Academic Veterinary Solutions; 2007. Pg 74-81, 84-89
- Pasquini C, Spurgeon TL, Pasquini S. Anatomy of domestic animals: systemic and regional approach. Pilot Point, TX: Sudz Pub.; 2003. Pg 587-592