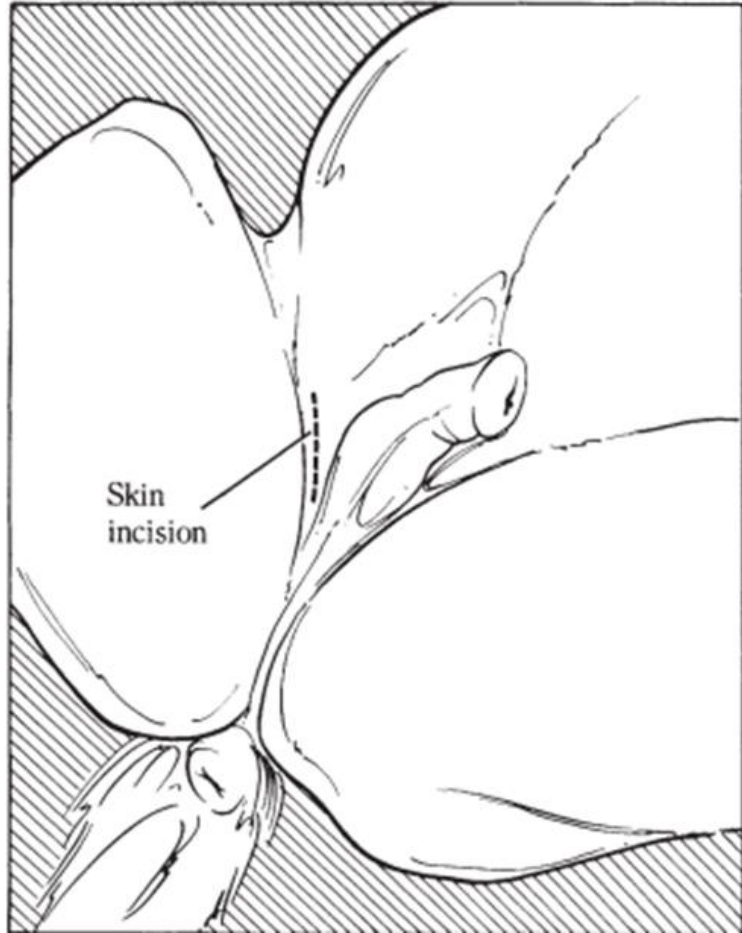



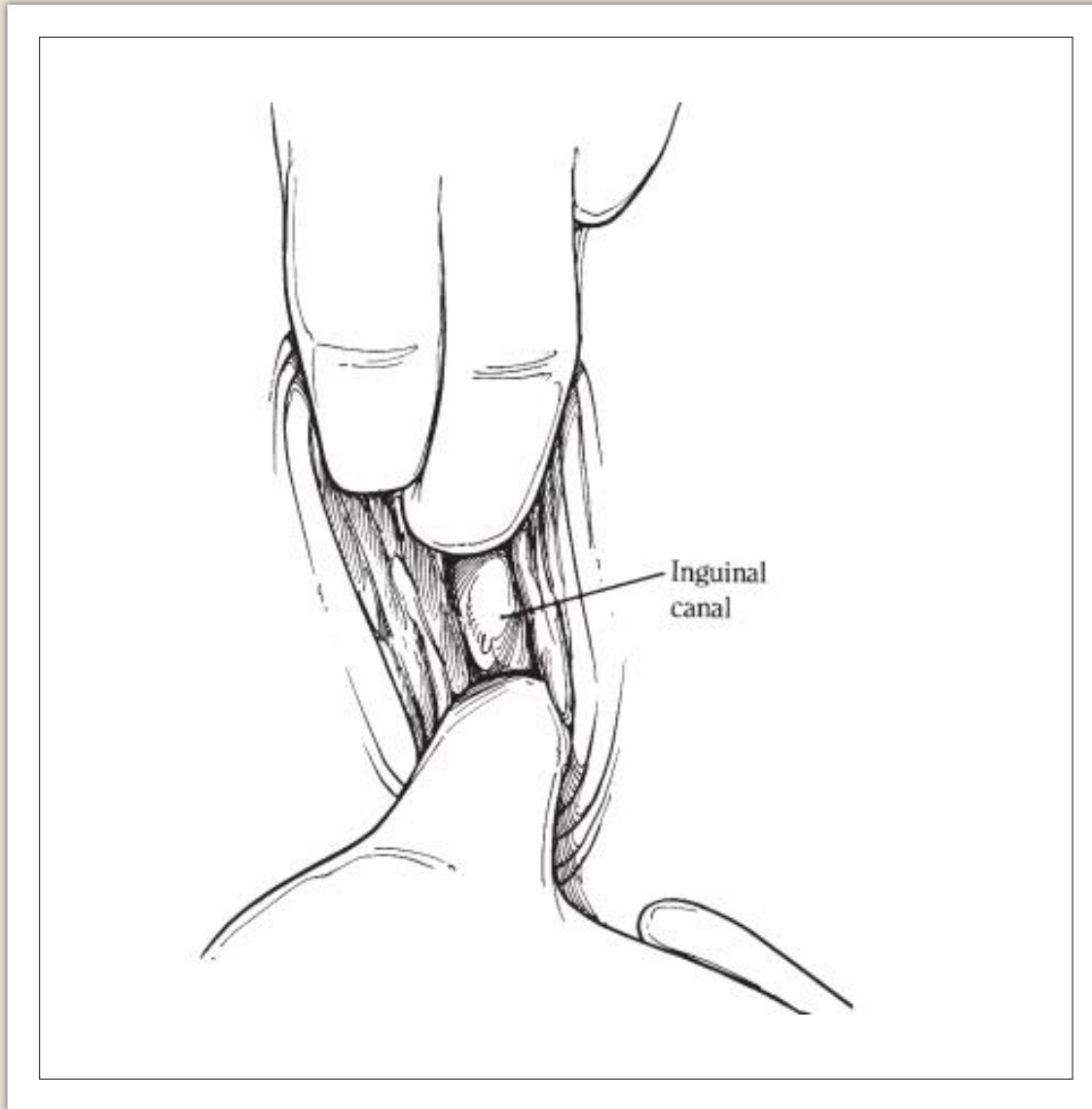
# **INGUINAL APPROACH**



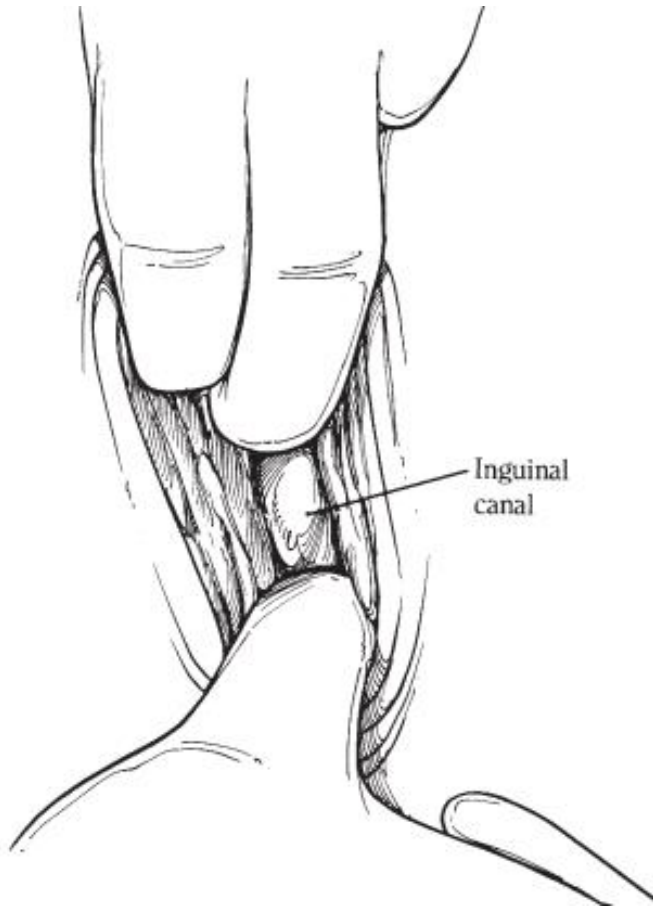
# STEPS INVOLVED



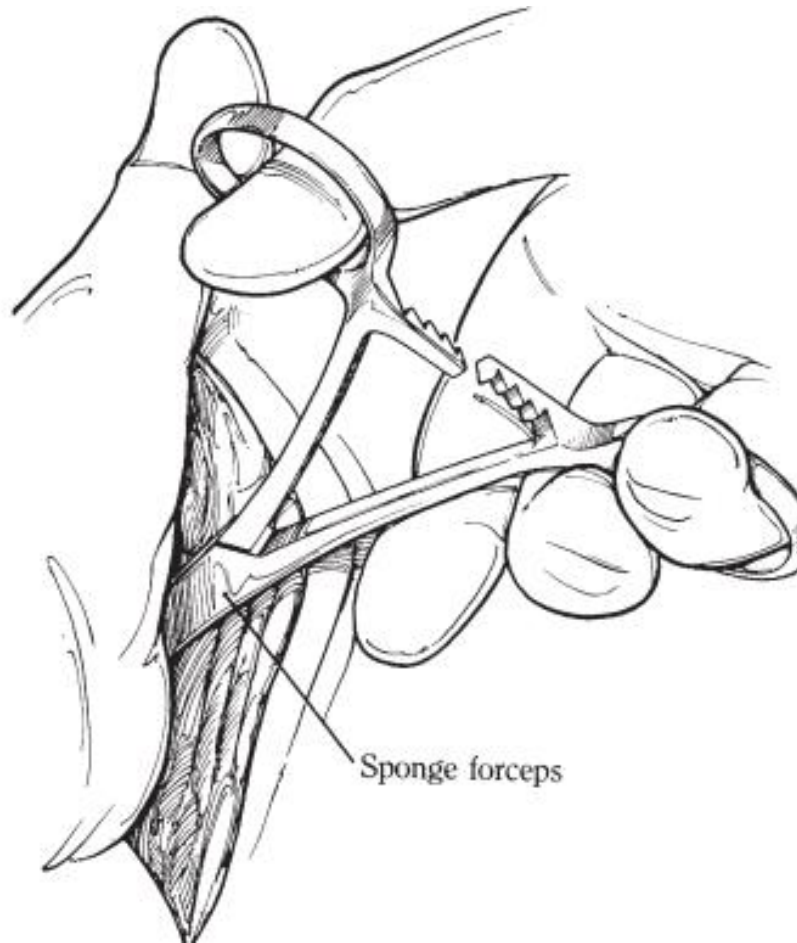
- Create a 12- to 15-cm skin incision is over the external inguinal ring and is continue through the superficial fascia.



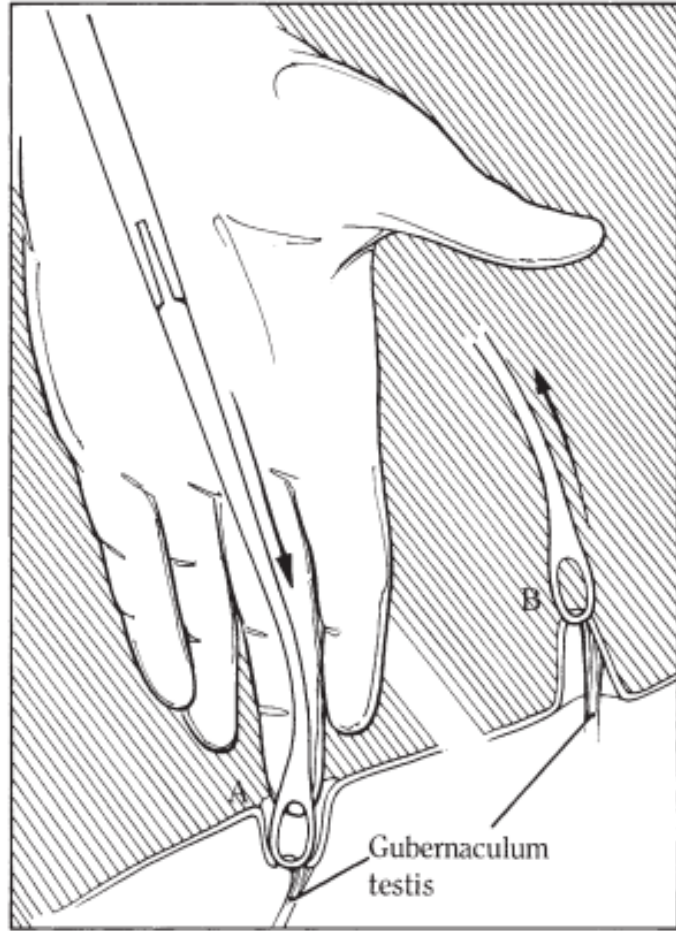
- Then, with fingertips, separate the subcutaneous inguinal fascia to expose the external inguinal ring. Large branches of the external pudendal vein are in this region, and trauma to these vessels should be avoided. Continue dissection beyond the external inguinal ring and through the inguinal canal until the vaginal ring is located with the finger.



- With an inguinal cryptorchid, the testis contained within the common vaginal tunic would be in the canal at this time.

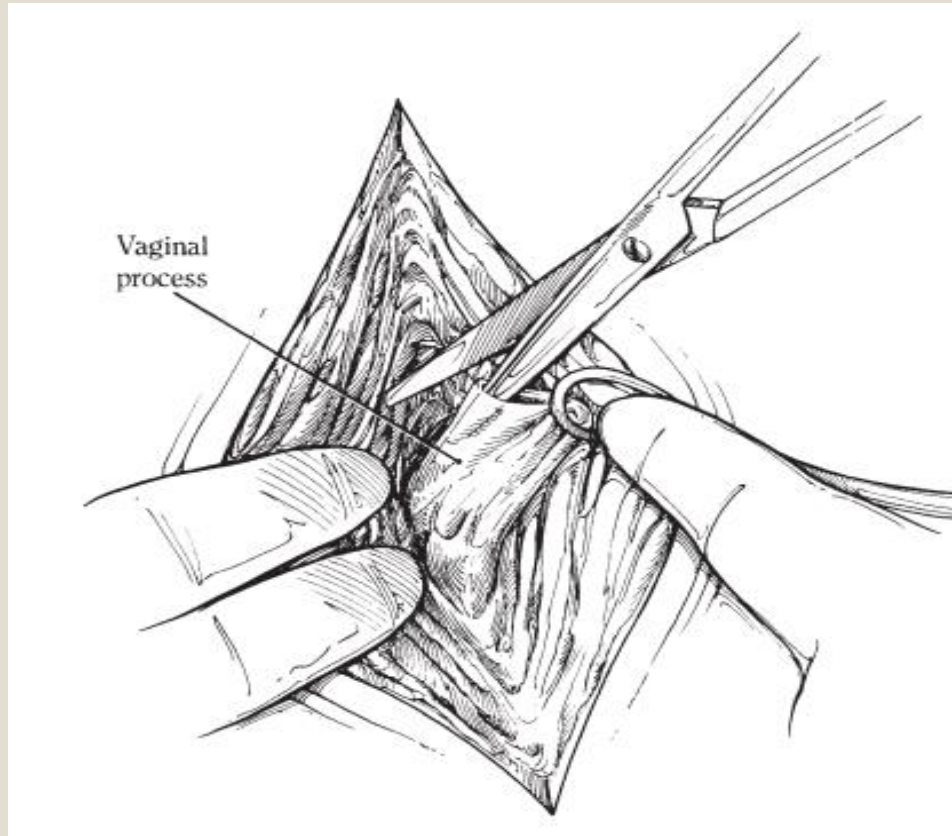


- Isolate the common tunic, and remove the testis as described for normal castration. A closed castration technique is generally used.
- With an abdominal cryptorchid, however, the testis will not be obvious. In this situation, locate the vaginal ring, and carefully introduce curved sponge forceps through the inguinal canal so that the jaws are placed through the vaginal ring into the vaginal process.

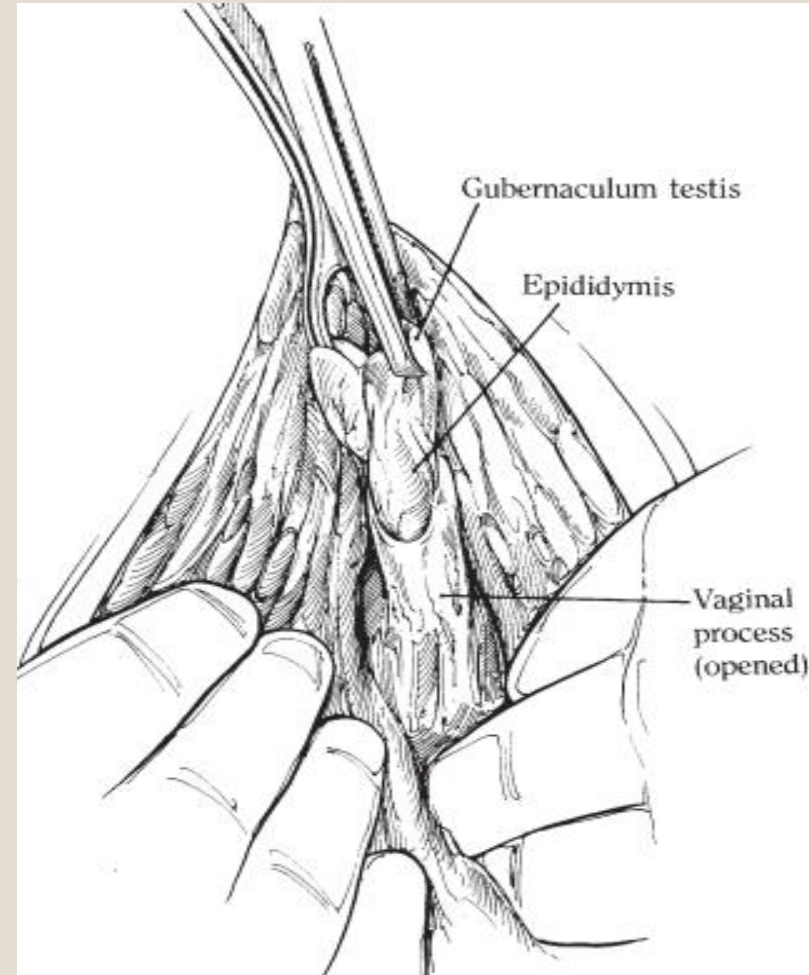


- Press the partially opened jaws of the forceps against the vaginal process and close.
- Using the forceps, grasp the vaginal process and associated gubernaculum testis, and then withdraw the forceps.

- Palpate the cordlike gubernaculum within the everted vaginal process by rolling it between the thumb and forefinger. When the gubernaculum is identified, open the vaginal process with Metzenbaum scissors

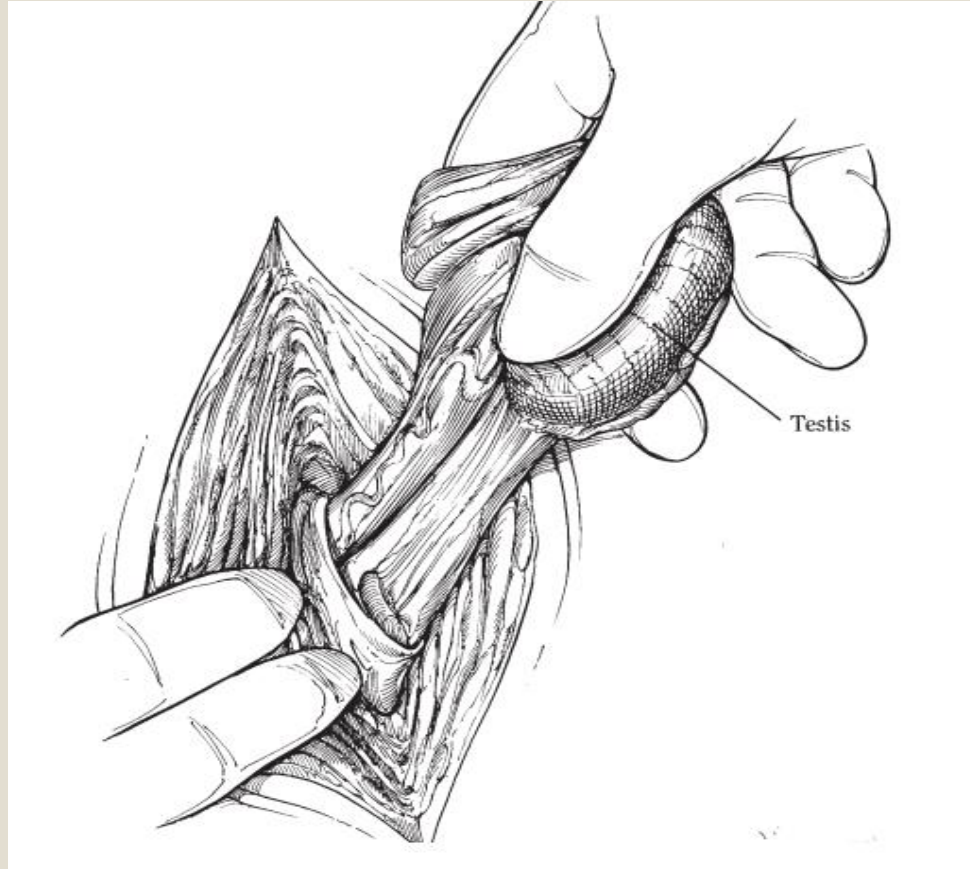


- and grasp the gubernaculum with Ochsner forceps. Traction on the gubernaculum causes the tail of the epididymis to be presented.

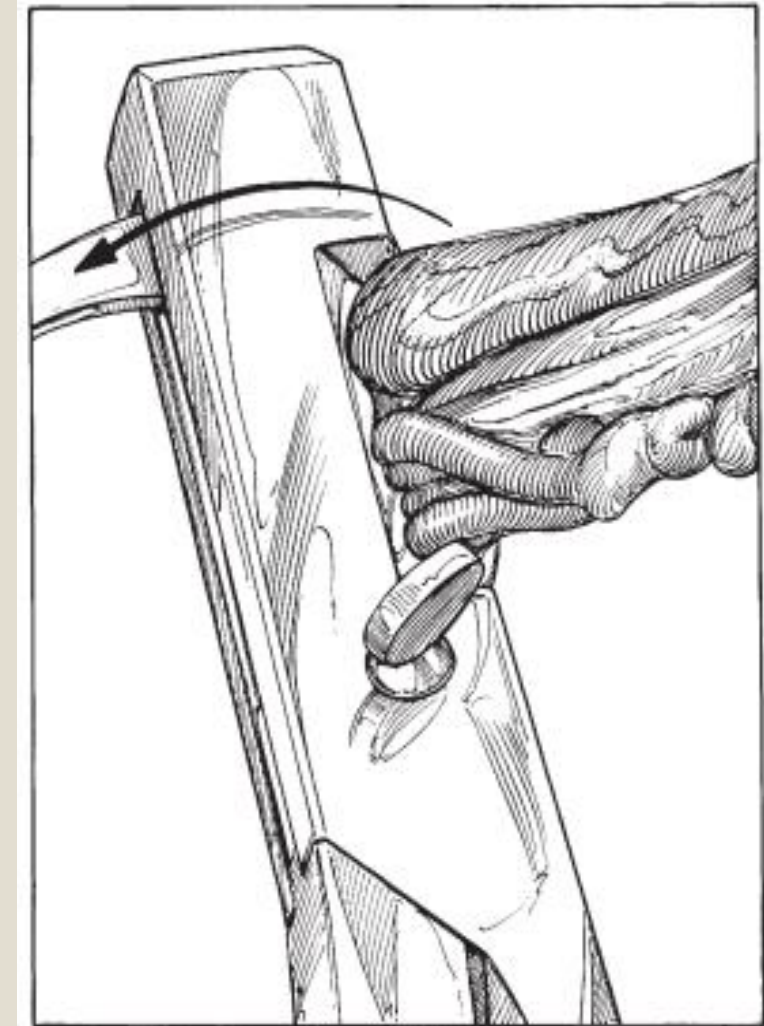


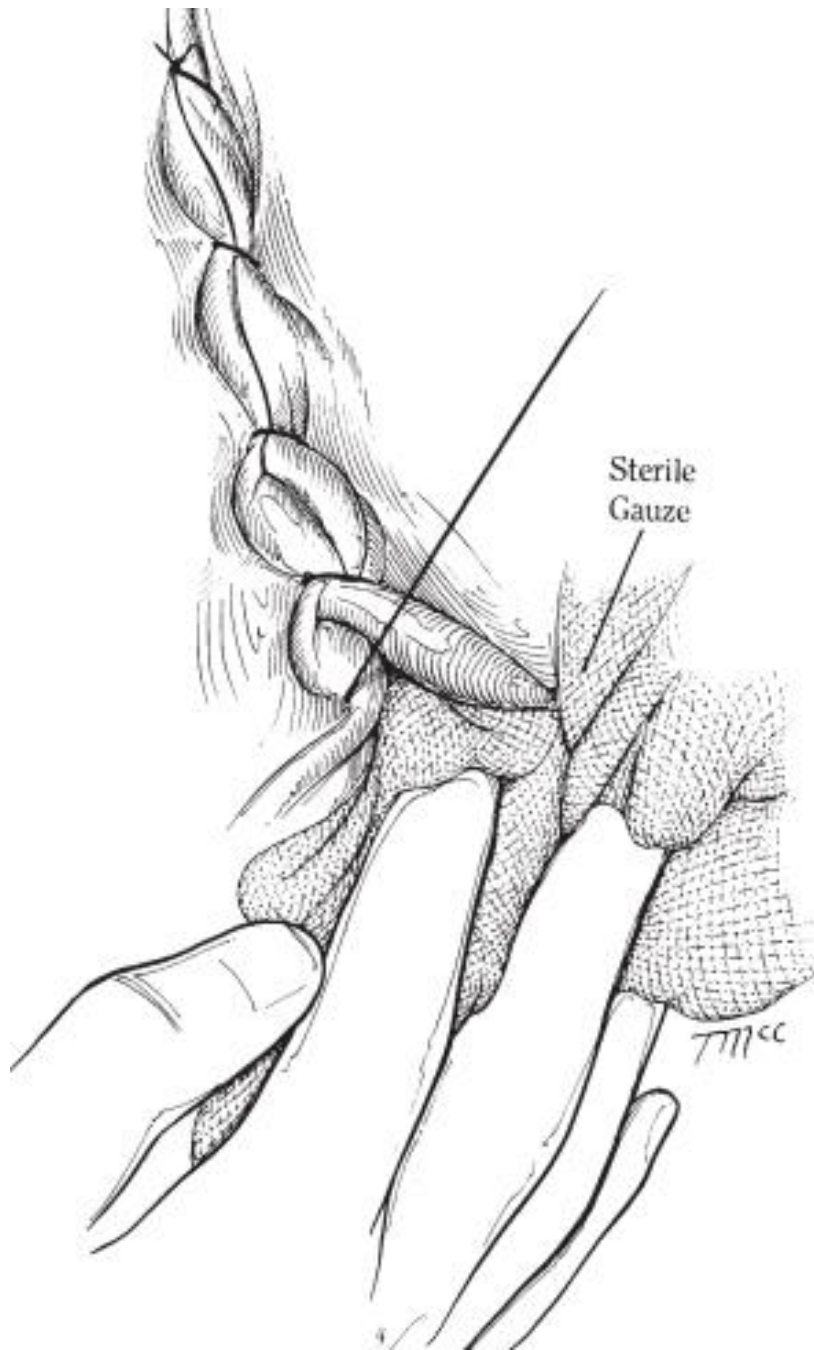


- Generally, gentle traction on the epididymis pulls the testis through the vaginal ring. Pushing around the vaginal ring with the fingers at the same time usually is sufficient to deliver the testis, but manual dilation of the vaginal ring is necessary in some cases. At this point, the testis is positively identified



- and is emasculated.





- In some instances, where the testis cannot be retracted sufficiently to enable emasculation, the cord is ligated and the testis sharply amputated. If the opening made in the vaginal process to deliver the testicle is considerable and if intestinal herniation is a possibility, the external inguinal ring is closed using a large-diameter synthetic absorbable suture material in either a preplaced interrupted pattern or a simple continuous pattern. The strong aponeurosis of the external abdominal oblique muscle is opposed to the fascia on the opposite side of the ring. The dead space is then closed using a no. 2-0 synthetic absorbable suture material. Conversely, a sterile gauze bandage may be packed over the external inguinal ring; this protects against herniation while normal swelling obliterates the inguinal canal. Finally, the skin is sutured with a synthetic absorbable suture, either in a continuous pattern or with simple interrupted sutures with long ends.

# Reference

- Hendrickson D. Techniques in Large Animal Surgery. 3rd ed. Ames: Blackwell Publishing;.