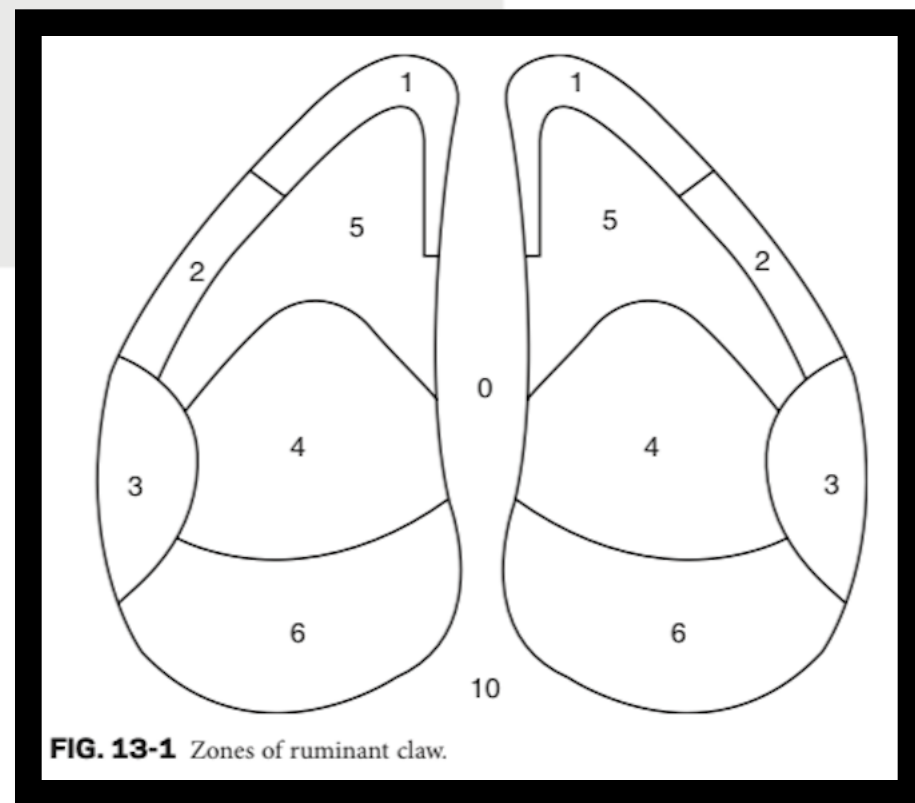


# Common Sites of Foot Lameness and Causes

Taken from: Farm Animal Medicine and Surgery, Graham Duncanson.

## Common Conditions of the Foot and Claw Horn

| Foot and Claw Condition          | Claw Zone                   | Cause   |
|----------------------------------|-----------------------------|---|
| Sole ulcer                       | 4                           | Overgrowth; laminitis   |
| Toe ulcer                        | 5 apex                      | Laminitis   |
| Thin sole toe ulcer              | 5 adjacent to zones 1 and 2 | Excessive wear  |
| Heel ulcer                       | 6 heel/sole junction        | Overgrowth; laminitis   |
| White line disease               | 3                           | Overgrowth; laminitis   |
| White line disease               | 1, 2                        | Laminitis   |
| Thin sole/heel                   | 4, 5, 6                     | Excessive wear  |
| Subsolar/heel abscess            | 4, 5, 6                     | Secondary to sole ulcer; white line disease; foreign body penetration |
| Sole/heel hemorrhage             | 4, 5, 6                     | Trauma; laminitis   |
| White line hemorrhage            | 1, 2, 3                     | Weight bearing; laminitis   |
| Vertical wall crack              | abaxial/axial wall          | Laminitis; trace mineral deficiency                                   |
| Horizontal wall crack single     | abaxial/axial wall          | Calving, weaning  |
| Horizontal wall crack multiple   | abaxial/axial wall          | Laminitis   |
| Heel erosion                     | 6, 10                       | Interdigital/digital dermatitis                                       |
| Interdigital dermatitis          | 0                           | Slurry, manure, moisture  |
| Interdigital hyperplasia (corn)  | 0                           | Chronic interdigital dermatitis                                       |
| Digital dermatitis               | 0, 10                       | Infectious agent  |
| Interdigital phlegmon (foot rot) | 0                           | <i>Fusobacterium</i>  |



**FIG. 13-1** Zones of ruminant claw.