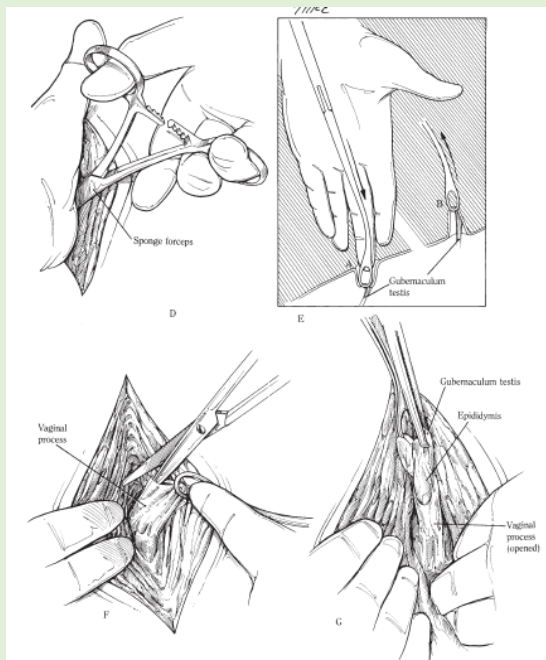


INGUINAL APPROACH

- Sharp dissection made over external inguinal ring, take care in avoiding external pudendal vein and its branches
- continue dissecting through inguinal canal until vaginal ring is located with a finger
- testes will be contained within the vaginal tunic and it is removed and castration is done using tools for open castration method

In the event of an abdominal cryptorchid

- Locate vaginal ring
- Use a curved sponge forceps to place things through inguinal canal through the vaginal ring and into the vaginal process
- Carefully identify and locate the gubernaculum
- By applying traction on the gubernaculum the tail of the epididymis is shown and with gently handling the testes can be pulled via the epididymis through the vaginal ring. (push against vaginal ring/apply manual dilation when needed)
- The testes is identified and can be emasculated



- If a large opening is made in the vaginal process then intestinal herniation is possible.
- Close the external inguinal ring using a large-diameter synthetic absorbable suture material in either a preplaced interrupted pattern or a simple continuous pattern
- Conversely, a sterile gauze bandage may be packed over the external inguinal ring.
- Suture skin with synthetic absorbable suture using a continuous pattern or with simple interrupted sutures with long ends

Packing will not be necessary if the opening of the vaginal process is small