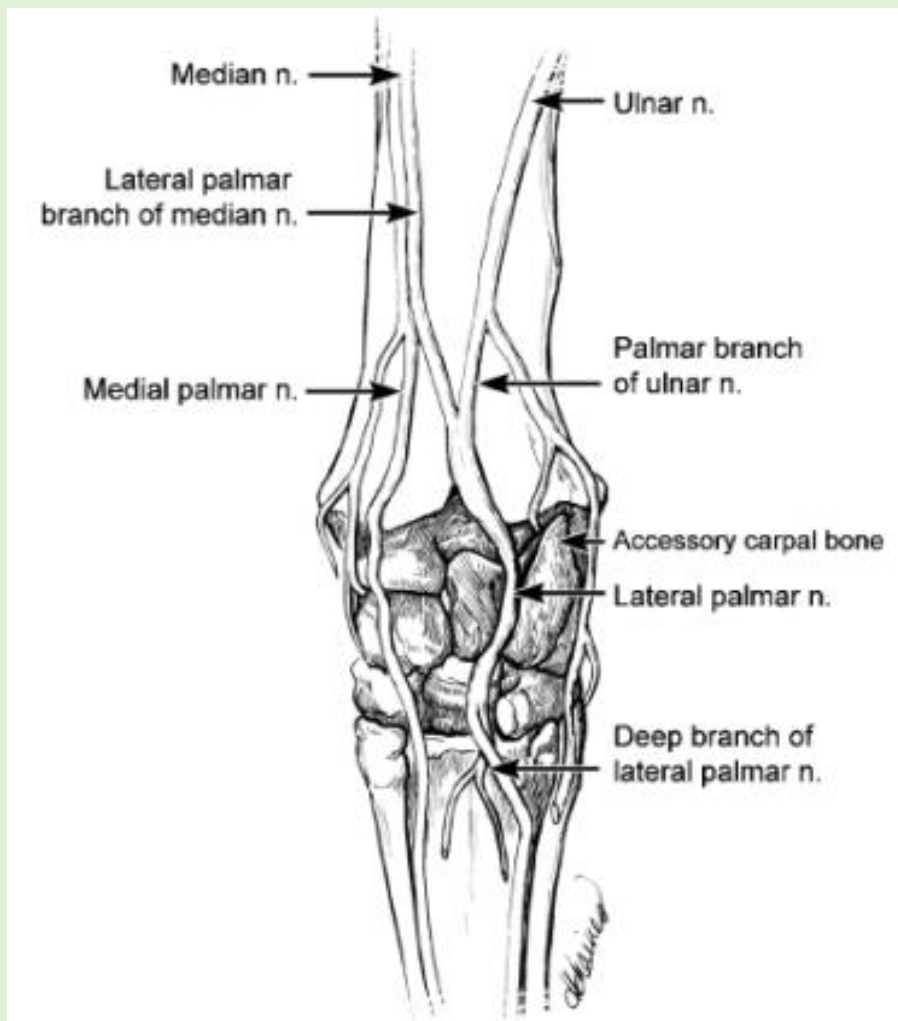


## Medial approach to lateral palmar nerve (forelimb) Nerve Block



*The lateral palmar nerve was injected at the medial aspect of the accessory carpal bone.*

*At this level, the lateral palmar branch of the median nerve has already fused with the palmar branch of the ulnar nerve to form the lateral palmar nerve which lies in a fascial plane on the medial aspect of the accessory carpal bone together with the lateral palmar vein and artery.*

### Procedure:

- Surgery is performed, with the limb bearing weight
- Insert a 25-gauge, 5/8-in. needle over the lateral palmar nerve where it courses over the medial aspect of the accessory carpal bone
- The needle is inserted in a medial to lateral direction at the distal third of a palpable groove, and 2 mL of local anaesthetic solution is deposited.
- Because the medial and lateral palmar metacarpal nerves arise from the deep branch of the lateral palmar nerve distal to this site, the structures they innervate, such as the proximal aspect of the suspensory ligament, are desensitized